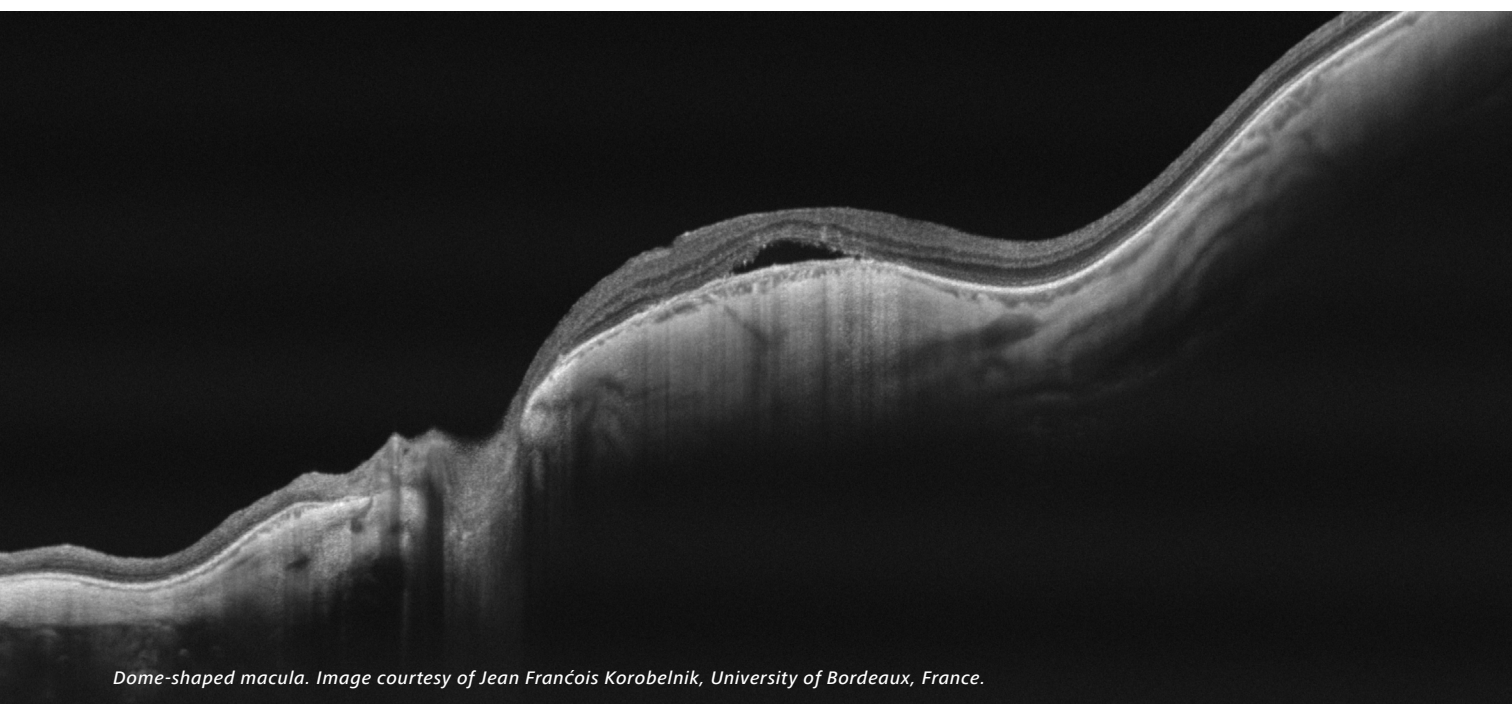


ZEISS PLEX Elite 9000

Swept-Source OCT & OCT Angiography



Dome-shaped macula. Image courtesy of Jean François Korobelnik, University of Bordeaux, France.

Clinical compendium of peer-reviewed journal articles

July 2020, Volume II



Seeing beyond

Contents

Click on topic to jump to that section.

Age-Related Macular Degeneration (AMD)	3
Anterior Segment – Vitreous	8
Choriocapillaris	9
Choroid	12
Diabetic Retinopathy	15
Glaucoma and Optic Neuropathies	18
Healthy Subjects	19
Inflammation	21
Myopia	23
Other Retina	24
Quantification	29
Swept-Source OCT & OCTA Technology	32
Tumors	36
Vascular Occlusions	37

Age-Related Macular Degeneration (AMD)

1. von der Emde L, Thiele S, Pfau M, Nadal J, Meyer J, Möller PT, Schmid M, Fleckenstein M, Holz FG, Schmitz-Valckenberg S. **Assessment of Exudative Activity of Choroidal Neovascularization in Age-Related Macular Degeneration by OCT Angiography.** *Ophthalmologica.* 2020 Mar;243(2):120-128. Epub 2019 Oct 30. <https://pubmed.ncbi.nlm.nih.gov/31665719>
2. Beck M, Joshi DS, Berger L, Klose G, De Zanet S, Mosinska A, Apostolopoulos S, Ebnetter A, Zinkernagel MS, Wolf S, Munk MR. **Comparison of Drusen Volume Assessed by Two Different OCT Devices.** *J Clin Med.* 2020 Aug 17;9(8):2657. <https://www.mdpi.com/2077-0383/9/8/2657/htm>
<https://pubmed.ncbi.nlm.nih.gov/32824455>
3. Nattagh K, Zhou H, Rinella N, Zhang Q, Dai Y, Foote KG, Keiner C, Deiner M, Duncan JL, Porco TC, Wang RK, Schwartz DM. **OCT Angiography to Predict Geographic Atrophy Progression using Choriocapillaris Flow Void as a Biomarker.** *Transl Vis Sci Technol.* 2020 Jun 3;9(7):6. <https://tvst.arvojournals.org/article.aspx?articleid=2766298>
<https://pubmed.ncbi.nlm.nih.gov/32832213>
4. Narita C, Wu Z, Rosenfeld PJ, Yang J, Lyu C, Caruso E, McGuinness M, Guymer RH. **Structural OCT Signs Suggestive of Subclinical Nonexudative Macular Neovascularization in Eyes With Large Drusen.** *Ophthalmology.* 2020 May;127(5):637-647. <https://pubmed.ncbi.nlm.nih.gov/31899036>
5. Fragiotta S, Fernández-Avellaneda P, Breazzano MP, Yannuzzi LA, Curcio CA, Freund KB. **Linear and Planar Reflection Artifacts On Swept-Source and Spectral-Domain Optical Coherence Tomography Due to Hyperreflective Crystalline Deposits.** *Graefes Arch Clin Exp Ophthalmol.* 2020 Mar;258(3):491-501. <https://pubmed.ncbi.nlm.nih.gov/31879821/>
6. Ohayon A, Sacconi R, Semoun O, Corbelli E, Souied EH, Querques G. **Choroidal Neovascular Area And Vessel Density Comparison Between Two Swept-Source Optical Coherence Tomography Angiography Devices.** *Retina.* 2020 Mar;40(3):521-528. <https://pubmed.ncbi.nlm.nih.gov/30589664/>
7. Cicinelli MV, Cavalleri M, Consorte AC, Rabiolo A, Sacconi R, Bandello F, Querques G. **Swept-Source and Spectral Domain Optical Coherence Tomography Angiography Versus Dye Angiography In the Measurement of Type 1 Neovascularization.** *Retina.* 2020 Mar;40(3):499-506. <https://pubmed.ncbi.nlm.nih.gov/30649078>
8. Sacconi R, Corbelli E, Borrelli E, Capone L, Carnevali A, Gelormini F, Querques L, Bandello F, Querques G. **Choriocapillaris Flow Impairment Could Predict the Enlargement of Geographic Atrophy Lesion.** *Br J Ophthalmol.* 2020 Mar 22. <https://pubmed.ncbi.nlm.nih.gov/32201374>
9. Keiko K, Jun K, Yuyako N, Ai F, Hiroki K, Yasuki I, Hiroko T. **Characteristics and Classification of Type 3 Neovascularization with B-Scan Flow Overlay and En Face Flow Images of Optical Coherence Tomography Angiography.** *Retina.* 2020 Jan;40(1):109-120. <https://pubmed.ncbi.nlm.nih.gov/30308559>
10. von der Emde L, Pfau M, Thiele S, Moller PT, Hassenrik R, Fleckenstein M, Holz FG, Schmitz-Valckenberg S. **Mesopic and Dark-Adapted Two-Color Fundus-Controlled Perimetry in Choroidal Neovascularization Secondary to Age-Related Macular Degeneration.** *Transl Vis Sci Technol.* 2019;8(1):7 <https://www.ncbi.nlm.nih.gov/pubmed/30637177>
11. Yang J, Zhang Q, Motulsky EH, Thulliez M, Shi Y, Lyu C, de Sistiernes L, Durbin MK, Feuer W, Wang RK, Gregori G, Rosenfeld PJ. **Two-Year Risk of Exudation in Eyes with Nonexudative Age-Related Macular Degeneration and Subclinical Neovascularization Detected with Swept Source Optical Coherence Tomography Angiography.** *Am J Ophthalmol.* 2019 Dec;208:1-11. <https://pubmed.ncbi.nlm.nih.gov/31229464/>

12. Braun PX, Mehta N, Gendelman I, Alibhai AY, Moulton EM, Zhao Y, Ishibazawa A, Sorour O, Konstantinou EK, Bauman CR, Witkin AJ, Fujimoto JG, Duker JS, Waheed NK. **Global Analysis of Macular Choriocapillaris Perfusion in Dry Age-Related Macular Degeneration using Swept-Source Optical Coherence Tomography Angiography.** *IOVS.* 2019 Dec 2;60(15):4985-4990. <https://pubmed.ncbi.nlm.nih.gov/31791062>
13. Keiner CM, Zhou H, Zhang Q, Wang RK, Rinella NT, Oldenburg CE, Duncan JL, Schwartz DM. **Quantifying choriocapillaris hypoperfusion in patients with choroidal neovascularization using swept-source OCT angiography.** *Clin Ophthalmol.* 2019 Aug 26;13:1613-1620. <https://pubmed.ncbi.nlm.nih.gov/31692580/>
14. Nassisi M, Shi Y, Fan W, Borrelli E, Uji A, Ip MS, Sadda SR. **Choriocapillaris Impairment around the Atrophic Lesions In Patients with Geographic Atrophy: A Swept-Source Optical Coherence Tomography Angiography Study.** *Br J Ophthalmol.* 2019 Jul;103(7):911-917. <https://pubmed.ncbi.nlm.nih.gov/30131381/>
15. Thulliez M, Zhang Q, Shi Y, Zhou H, Chu Z, de Sistiernes L, Durbin MK, Feuer W, Gregori G, Wang RK, Rosenfeld PJ. **Correlations between Choriocapillaris Flow Deficits around Geographic Atrophy and Enlargement Rates Based on Swept-Source OCT Imaging.** *Ophthalmol Retina.* 2019 Jun;3(6):478-488. <https://pubmed.ncbi.nlm.nih.gov/31174669>
16. Corvi F, Cozzi M, Barbolini E, Nizza D, Belotti M, Staurengi G, Giani A. **Comparison Between Several Optical Coherence Tomography Angiography Devices And Indocyanine Green Angiography Of Choroidal Neovascularization.** *Retina.* 2019 May;40(5):873-880. <https://pubmed.ncbi.nlm.nih.gov/30807517>
17. Shi Y, Motulsky H, Goldhardt R, Yehoshua Z, Thulliez M, Feuer W, Gregori G, Rosenfeld PJ. **Predictive Value of the OCT Double-Layer Sign for Identifying Subclinical Neovascularization in Age-Related Macular Degeneration.** *Ophthalmol Retina.* 2019 Mar;3(3):211-219. <https://pubmed.ncbi.nlm.nih.gov/31014697/>
18. Parravano M, Borrelli E, Sacconi R, Costanzo E, Marchese A, Manca D, Varano M, Bandello F, Querques G. **A Comparison Among Different Automatically Segmented Slabs to Assess Neovascular AMD using Swept Source OCT Angiography.** *Transl Vis Sci Technol.* 2019 Mar 27;8(2):8. <https://pubmed.ncbi.nlm.nih.gov/30941265>
19. Thulliez M, Motulsky H, Feuer W, Gregori G, Rosenfeld PJ. **En Face Imaging of Geographic Atrophy Using Different Swept-Source OCT Scan Patterns.** *Ophthalmol Retina.* 2019 Feb;3(2):122-132. <https://pubmed.ncbi.nlm.nih.gov/31014759>
20. Ohayon A, Sacconi R, Semoun O, Corbelli E, Souied EH, Querques G. **Choroidal Neovascular Area and Vessel Density Comparison between Two Swept-Source Optical Coherence Tomography Angiography Devices.** *Retina.* 2018 <https://www.ncbi.nlm.nih.gov/pubmed/30589664>
21. Namavari A, Zheng F, Motulsky EH, de Oliveira Dias JR, Gregori G, Rosenfeld PJ. **Swept-Source OCT Angiography Identifies Choroidal Neovascularization Arising from a Choroidal Nevus.** *Ophthalmic Surg Lasers Imaging Retina.* 2018;49(5):360 <https://www.ncbi.nlm.nih.gov/pubmed/29772047>
22. Motulsky, EH, Zheng, F, Shi, Y, Gregori, G, Rosenfeld, PJ. **Anatomic Localization of Type 1 and Type 2 Macular Neovascularization Using Swept-Source OCT Angiography.** *Ophthalmic Surg Lasers Imaging Retina.* 2018;49(11):878 <https://www.ncbi.nlm.nih.gov/pubmed/30457647>
23. Marchese A, Arrigo A, Sacconi R, Querques, Prascina F, Pierro L, Bandello, Querques G. **Spectrum of Choroidal Neovascularisation Associated with Dome-Shaped Macula.** *Br J Ophthalmol.* 2018 <https://www.ncbi.nlm.nih.gov/pubmed/30327318>
24. de Oliveira Dias JR, Zhang Q, Garcia JMB, Zheng F, Motulsky EH, Roisman L, Miller A, Chen CL, Kubach S, de Sistiernes L, Durbin MK, Feuer W, Wang RK, Gregori G, Rosenfeld PJ. **Natural History of Subclinical Neovascularization in Nonexudative Age-Related Macular Degeneration Using Swept-Source OCT Angiography.** *Ophthalmology.* 2018 Feb;125(2):255-266. Epub 2017 Sep 28. <https://www.ncbi.nlm.nih.gov/pubmed/28964581>

25. Dansingani KK, Gal-Or O, Sadda SR, Yannuzzi LA, Freund KB. **Understanding Aneurysmal Type 1 Neovascularization (Polypoidal Choroidal Vasculopathy): A Lesson in the Taxonomy of 'Expanded Spectra' – a Review.** *Clin Exp Ophthalmol.* 2018;46(2):189 <https://www.ncbi.nlm.nih.gov/pubmed/29178419>
26. Carnevali A, Sacconi R, Querques L, Corbelli E, Rabiolo A, Chiara G, Scorcia V, Bandello F, Querques G. **Abnormal Quiescent Neovascularization in a Patient with Large Colloid Drusen Visualized by Optical Coherence Tomography Angiography.** *Retin Cases Brief Rep.* 2018;12 Suppl 1:S41 <https://www.ncbi.nlm.nih.gov/pubmed/29064855>
27. Borrelli E, Shi Y, Uji A, Balasubramanian S, Nassisi M, Sarraf D, Sadda SR. **Topographic Analysis of the Choriocapillaris in Intermediate Age-Related Macular Degeneration.** *Am J Ophthalmol.* 2018;196:34 <https://www.ncbi.nlm.nih.gov/pubmed/30118688>
28. Sacconi R, SD, Garrity S, Freund KB, Yannuzzi LA, Gal-Or O, Souied E, Sieiro A, Corbelli E, Carnevali A, Querques L. **Abstracts.** *Ophthalmology.* 2018;125(12):1834
29. Zheng F, Motulsky EH, de Oliveira Dias JR, de Lopez EP, Gregori G, Rosenfeld PJ. **OCT Angiography Helps Distinguish between Proliferative Macular Telangiectasia Type 2 and Neovascular Age-Related Macular Degeneration.** *Ophthalmic Surg Lasers Imaging Retina.* 2018;49(5):303 <https://www.ncbi.nlm.nih.gov/pubmed/29772040>
30. Qin J, Rinella N, Zhang Q, Zhou H, Wong J, Deiner M, Roorda A, Porco TC, Wang RK, Schwartz DM, Duncan JL. **OCT Angiography and Cone Photoreceptor Imaging in Geographic Atrophy.** *Invest Ophthalmol Vis Sci.* 2018 Dec 3;59(15):5985-92 <https://www.ncbi.nlm.nih.gov/pubmed/30572343>
31. Lek J, Caruso E, Baglin EK, Sharangan P, Hodgson L, Harper C, Rosenfeld PJ, Luu CD, Guymer RH. **Interpretation of Subretinal Fluid Using OCT in Intermediate Age-Related Macular Degeneration.** *Ophthalmol Retina.* 2018 Aug;2(8):792-802. <https://pubmed.ncbi.nlm.nih.gov/31047532>
32. Muller PL, Pfau M, Moller PT, Nadal J, Schmid M, Lindner M, de Sisternes L, Stohr H, Weber BHF, Neuhaus C, Herrmann P, Schmitz-Valckenberg S, Holz FG, Fleckenstein M. **Choroidal Flow Signal in Late-Onset Stargardt Disease and Age-Related Macular Degeneration: An OCT-Angiography Study.** *Invest Ophthalmol Vis Sci.* 2018 Mar 20;59(4):AMD122-31 <https://www.ncbi.nlm.nih.gov/pubmed/30140905>
33. Zhang Q, Zheng , Motulsky EH, Gregori G, Chu Z, Chen CL, Li C, de Sisternes , Durbin M, Rosenfeld PJ, Wang RK. **A Novel Strategy for Quantifying Choriocapillaris Flow Voids Using Swept-Source OCT Angiography.** *Invest Ophthalmol Vis Sci.* 2018 Jan 1;59(1):203-11 <https://www.ncbi.nlm.nih.gov/pubmed/29340648>
34. Dias JR, Zhang Q, Roisman L, Zheng F, Chen C-L, Miller AR, Motulsky EH, Liu G, Kubach , De Sisternes L, Feuer WJ, Gregor G, Durbin MK, Wang RK, Rosenfeld PJ. **Prevalence of Quiescent Neovascularization in Intermediate and Late Non-Exudative Age-Related Macular Degeneration and the Incidence of Subsequent Exudation Using Swept-Source Optical Coherence Tomography Angiography.** *Invest Ophthalmol Vis Sci.* 2017;58(8):55 <https://iovs.arvojournals.org/article.aspx?articleid=2637170&resultClick=1>
35. Rabiolo A, Sacconi R, Cicinelli MV, Querques L, Bandello F, Querques G. **Spotlight on Reticular Pseudodrusen.** *Clin Ophthalmol.* 2017;11:1707 <https://www.ncbi.nlm.nih.gov/pubmed/29033536> <https://www.dovepress.com/getfile.php?fileID=38507>
36. Zhang Q, Zhang A, Lee CS, Lee AY, Rezaei KA, Roisman L, Miller A, Zheng F, Gregori G, Durbin MK, An L, Stetson PF, Rosenfeld PJ, Wang RK. **Projection Artifact Removal Improves Visualization and Quantitation of Macular Neovascularization Imaged by Optical Coherence Tomography Angiography.** *Ophthalmol Retina.* 2017;1(2):124 <https://www.ncbi.nlm.nih.gov/pubmed/28584883>

37. Zheng F, Zhang Q, Motulsky EH, de Oliveira Dias JR, Chen CL, Chu Z, Miller AR, Feuer W, Gregori G, Kubach S, Durbin MK, Wang RK, Rosenfeld PJ. **Comparison of Neovascular Lesion Area Measurements from Different Swept-Source OCT Angiographic Scan Patterns in Age-Related Macular Degeneration.** *Invest Ophthalmol Vis Sci.* 2017 Oct 1;58(12):5098-104 <https://www.ncbi.nlm.nih.gov/pubmed/28986595>
<https://www.ncbi.nlm.nih.gov/pmc/articles/PMC5634352/pdf/i1552-5783-58-12-5098.pdf>
38. Zheng F, Zhang Q, Miller AR, Dias JR, Motulsky EH, Liu G, Chu Z, Chen C-L, Kubach S, De Sisternes L, Feuer W, Gregori G, Durbin MK, Wang RK, Rosenfeld PJ. **Comparing Area Measurements of Choroidal Neovascularization Obtained Using Different Swept-Source OCT Angiographic Scan Patterns in Neovascular Age-Related Macular Degeneration.** *Invest Ophthalmol Vis Sci.* 2017 Jun;58(8):50
<https://iovs.arvojournals.org/article.aspx?articleid=2637946&resultClick=1>
39. Stein G, Zheng F, Tran AQ, Dias JR, Motulsky EH, Gregori G, Rosenfeld PJ. **Swept-Source OCT Angiography of Polypoidal Choroidal Vasculopathy Using Boundary Layer Specific Segmentation.** *Invest Ophthalmol Vis Sci.* 2017 Jun;58(8):1698 <https://iovs.arvojournals.org/article.aspx?articleid=2637816&resultClick=1>
40. Motulsky EH, Stein G, Zhang Q, Chen C-L, Zheng F, Liu G, Dias JR, Feuer W, Wang RK, Gregori G, Rosenfeld PJ. **Correlations between the Volumes of Fibrovascular Retinal Pigment Epithelial Detachments and the Areas of Type 1 Choroidal Neovascularization in Age-Related Macular Degeneration Using OCT Imaging.** *Invest Ophthalmol Vis Sci.* 2017 Jun;58(8):369 <https://iovs.arvojournals.org/article.aspx?articleid=2637133&resultClick=1>
41. Kubach S, Lewis W, Gregori G, Rosenfeld PJ. **Retinal Pigment Epithelium Layer Segmentation Accuracy on Widefield High-resolution Optical Coherence Tomography Cubes.** *Invest Ophthalmol Vis Sci.* 2017 Jun;58(8):661
<https://iovs.arvojournals.org/article.aspx?articleid=2637966&resultClick=1>
42. De Sisternes L, Bagherinia H, Kubach S, Knighton RW, Zheng F, Gregori G, Rosenfeld PJ, Durbin M. **Automated Case-Adaptive Slab Configuration for Visualization of Choroidal Neovascularization in Swept-Source OCT Angiography.** *Invest Ophthalmol Vis Sci.* 2017 Jun;58(8):372
<https://iovs.arvojournals.org/article.aspx?articleid=2637935&resultClick=1>
43. Zhang Q, Chen C-L, Chu Z, Zheng F, Miller A, Roisman L, de Oliveira Dias JR, Yehoshua Z, Schaal KB, Feuer W. **Automated Quantitation of Choroidal Neovascularization: A Comparison Study between Spectral-Domain and Swept-Source OCT Angiograms automated Cnv Quantitation Using OCTA.** *Invest Ophthalmol Vis Sci.* 2017 Mar;58(3):1506-13 <https://iovs.arvojournals.org/article.aspx?articleid=2610163>
44. Miller AR, Roisman L, Zhang Q, Zheng F, Rafael de Oliveira Dias J, Yehoshua Z, Schaal KB, Feuer W, Gregori G, Chu Z, Chen CL, Kubach S, An L, Stetson PF, Durbin MK, Wang RK, Rosenfeld PJ. **Comparison between Spectral-Domain and Swept-Source Optical Coherence Tomography Angiographic Imaging of Choroidal Neovascularization.** *Invest Ophthalmol Vis Sci.* 2017 Mar 1;58(3):1499-1505
<https://www.ncbi.nlm.nih.gov/pubmed/28273316>
<https://www.ncbi.nlm.nih.gov/pmc/articles/PMC5361583/pdf/i1552-5783-58-3-1499.pdf>
45. Jung JJ, Chen MH, Chung Y, Lee SS. **Swept-Source Optical Coherence Tomography Angiography for Choroidal Neovascularization after Bevacizumab and Photodynamic Therapy.** *Amer J Ophthalmol Case Reports.* 2016;1:1
<http://www.sciencedirect.com/science/article/pii/S245199361530013X>
46. Zheng F, Gregori G, Schaal KB, Legarreta AD, Miller AR, Roisman L, Feuer WJ, Rosenfeld PJ. **Choroidal Thickness and Choroidal Vessel Density in Nonexudative Age-Related Macular Degeneration Using Swept-Source Optical Coherence Tomography Imaging.** *Invest Ophthalmol Vis Sci.* 2016;57(14):6256-6256
<https://www.ncbi.nlm.nih.gov/pubmed/27849311>
<https://www.ncbi.nlm.nih.gov/pmc/articles/PMC5114036/pdf/i1552-5783-57-14-6256.pdf>

47. Zheng F, Roisman L, Schaal KB, Miller AR, Robbins G, Gregori G, Rosenfeld PJ. **Artifactual Flow Signals within Drusen Detected by OCT Angiography.** *Ophthalmic Surg Lasers Imaging Retina.* 2016;47(6):517
<https://www.ncbi.nlm.nih.gov/pubmed/27327280>
48. Miller A, Zheng F, Schaal KB, Roisman L, Legarreta AD, Feuer W, Rosenfeld PJ, Gregori G. **Widefield Swept-Source OCT Choroidal Thickness Maps and Choroidal Vessel Distribution in Eyes with Dry Age-Related Macular Degeneration.** *Invest Ophthalmol Vis Sci.* 2016 Sep;57(12):4942
<https://iovs.arvojournals.org/article.aspx?articleid=2563115&resultClick=1>
49. Roisman L, Qinquin Z, Ruikang KW, Gregori G, Zhang A, Chen CL, et al. **Swept-Source Optical Coherence Tomography Angiography of Asymptomatic Neovascularization in Intermediate Age-Related Macular Degeneration.** *Invest Ophthalmol Vis Sci.* 2016 Sep;57(12):4939
<https://iovs.arvojournals.org/article.aspx?articleid=2563112&resultClick=1>
50. Zhang Q, Zhang A, Lee CS, Lee A, Roisman L, Gregori G, Durbin M, An L, Stetson PF, Rosenfeld PJ, Wang RK. **OCT-Based Angiography of Choroidal Neovascularization by Removing Projection Artifacts.** *Invest Ophthalmol Vis Sci.* 2016 Sep;57(12) <https://iovs.arvojournals.org/article.aspx?articleid=2558422&resultClick=1>
51. Roisman L, Zhang Q, Wang RK, Gregori G, Zhang A, Chen CL, Durbin MK, An L, Stetson PF, Robbins G, Miller A, Zheng F, Rosenfeld PJ. **Optical Coherence Tomography Angiography of Asymptomatic Neovascularization in Intermediate Age-Related Macular Degeneration.** *Ophthalmology.* 2016 Jun;123(6):1309-19. Epub 2016 Feb 12.
<https://www.ncbi.nlm.nih.gov/pubmed/26876696>
<https://www.ncbi.nlm.nih.gov/pmc/articles/PMC5120960/pdf/nihms830277.pdf>
52. Schaal KB, Legarreta AD, Feuer W, Gregori G, Cheng Q, Legarreta J, Stetson PF, Kubach S, Rosenfeld PJ. **Masked Assessment of Widefield En Face Swept-Source OCT Imaging Versus Color, Autofluorescence, and Infrared Fundus Imaging for the Diagnosis of Reticular Pseudodrusen.** *Invest Ophthalmol Vis Sci.* 2016 Sep;57(12):1609
<https://iovs.arvojournals.org/article.aspx?articleid=2560239&resultClick=1>
53. Schaal KB, Legarreta AD, Gregori G, Legarreta JE, Cheng Q, Stetson PF, Cai M, Laron M, Durbin M, Rosenfeld PJ. **Widefield En Face Optical Coherence Tomography Imaging of Subretinal Drusenoid Deposits.** *Ophthalmic Surg Lasers Imaging Retina.* 2015;46(5):550 <https://www.ncbi.nlm.nih.gov/pubmed/26057758>
<https://www.healio.com/ophthalmology/journals/osli/2015-5-46-5/{ab88275a-55a9-4562-be3d-203ec772e063}/widefield-en-face-optical-coherence-tomography-imaging-of-subretinal-drusenoid-deposits>

Anterior Segment – Vitreous

1. Ang M, Devarajan K, Tan AC, Ke M, Tan B, Teo K, Sng CCA, Ting DS, Schmetterer L. **Anterior Segment Optical Coherence Tomography Angiography for Iris Vasculature In Pigmented Eyes.** *Br J Ophthalmol.* Epub 2020 Aug 18 <https://pubmed.ncbi.nlm.nih.gov/32816800/>
2. Patricia D. Nale, ELS; Netan Choudhry, MD, FRCS. **YAG Vitreolysis Resolves Floaters In Select Cases.** *Ocular Surgery News.* Epub 2020 Jul 27. <https://www.healio.com/news/ophthalmology/20200727/yag-vitreolysis-resolves-floaters-in-select-cases>
3. D'Aloisio R, Viggiano P, Borrelli E, Parravano M, Agbèanda AG, Evangelista F, Ferro G, Toto L, Mastropasqua R. **Changes in Iris Perfusion Following Scleral Buckle Surgery for Rhegmatogenous Retinal Detachment: An Anterior Segment Optical Coherence Tomography Angiography (AS-OCTA) Study.** *J Clin Med.* 2020 Apr 24;9(4):1231. <https://pubmed.ncbi.nlm.nih.gov/32344742>
4. Aicher NT, Nagahori K, Inoue M, Itoh Y, Hirakata A. **Vascular Density of Anterior Segment of Eye Determined By Optical Coherence Tomography Angiography and Slit-Lamp Photography.** *Ophthalmic Res.* 2020 Mar 5. <https://pubmed.ncbi.nlm.nih.gov/32135544/>
5. Cozzi M, Staurenghi G, Invernizzi A. **Anterior Segment and Ocular Adnexa OCT Angiography.** *Ophthalmology.* 2020 Feb;127(2):220. <https://pubmed.ncbi.nlm.nih.gov/31973834/>
1. Leong BCS, Fragiotta S, Kaden TR, Freund KB, Zweifel S, Engelbert M. **OCT En Face Analysis of the Posterior Vitreous Reveals Topographic Relationships among Premacular Bursa, Prevascular Fissures, and Cisterns.** *Ophthalmol Retina.* 2020 Jan;4(1):84-89. <https://pubmed.ncbi.nlm.nih.gov/31735635>
2. Hirano T, Hoshiyama K, Hirabayashi K, Wakabayashi M, Toriyama Y, Tokimitsu M, Murata T. **Vitreoretinal Interface Slab in OCT Angiography for Detecting Diabetic Retinal Neovascularization.** *Ophthalmol Retina.* 2020 Jun;4(6):588-594. Epub 2020 Jan 10. <https://pubmed.ncbi.nlm.nih.gov/32107187>
3. Mastropasqua R, D'Aloisio R, Viggiano P, Borrelli E, Iafigliola C, Di Nicola M, Aharrh-Gnama A, Di Marzio G, Toto L, Mariotti C, Carpineto P. **Early Retinal Flow Changes After Vitreoretinal Surgery In Idiopathic Epiretinal Membrane Using Swept Source Optical Coherence Tomography Angiography.** *J Clin Med.* 2019 Dec; 8(12): 2067. Epub 2019 Nov 24. <https://www.ncbi.nlm.nih.gov/pmc/articles/PMC6947278/>
<https://pubmed.ncbi.nlm.nih.gov/31771299>
4. Lee WD, Devarajan K, Chua J, Schmetterer L, Mehta JS, Ang M. **Optical Coherence Tomography Angiography for the Anterior Segment.** *Eye Vis (Lond).* 2019 Feb 1;6:4. <https://link.springer.com/article/10.1186/s40662-019-0129-2>
<https://pubmed.ncbi.nlm.nih.gov/30775387>

Choriocapillaris

1. Chu Z, Pepple KL, Wang RK. **Quantitative Analysis of Choriocapillaris in Uveitic and Normal Subjects with SS-OCT Angiography.** *Am J Ophthalmol.* 2020 Oct;218:17-27. <https://pubmed.ncbi.nlm.nih.gov/32413411/>
2. Chu Z, Weinstein JE, Wang RK, Pepple KL. **Quantitative Analysis of the Choriocapillaris in Uveitis Using en face Swept Source Optical Coherence Tomography Angiography.** *Am J Ophthalmol.* 2020 Oct;218:17-27. Epub 2020 May 12 <https://pubmed.ncbi.nlm.nih.gov/32413411>
3. Ledesma-Gil G, Fernandez-Avellaneda P, Spaide RF, **Swept-Source Optical Coherence Tomography Angiography Image Compensation of the Choriocapillaris Induces Artifacts.** *Retina.* 2020 Oct;40(10):1865-1872. <https://pubmed.ncbi.nlm.nih.gov/32453067>
4. Lin E, Ke M, Tan B, Yao X, Wong D, Ong L, Schmetterer L, Chua J. **Are Choriocapillaris Flow Void Features Robust to Diurnal Variations? A Swept-Source Optical Coherence Tomography Angiography (OCTA) Study.** *Sci. Rep.* 2020 Jul 9;10(1):11249. <https://pubmed.ncbi.nlm.nih.gov/32647298>
5. Su L, Ji YS, Tong N, Sarraf D, He X, Sun X, Xu X, Sadda SR. **Quantitative Assessment of the Retinal Microvasculature and Choriocapillaris In Myopic Patients Using Swept-Source Optical Coherence Tomography Angiography.** *Graefes Arch Clin Exp Ophthalmol.* 2020 Jun;258(6):1173-1180. Epub 2020 Mar 6. <https://pubmed.ncbi.nlm.nih.gov/32144487/>
6. Nattagh K, Zhou H, Rinella N, Zhang Q, Dai Y, Foote KG, Keiner C, Deiner M, Duncan JL, Porco TC, Wang RK, Schwartz DM. **OCT Angiography to Predict Geographic Atrophy Progression Using Choriocapillaris Flow Void as a Biomarker.** *TVST.* 2020 Jun 3;9(7):6. <https://tvst.arvojournals.org/article.aspx?articleid=2766298> <https://pubmed.ncbi.nlm.nih.gov/32832213>
7. Byon I, Alagorie AR, Ji Y, Su L, Sadda SR. **Optimizing the Repeatability of Choriocapillaris Flow Deficit Measurement from Optical Coherence Tomography Angiography.** *Am J Ophthalmol.* 2020 May 23;219:21-32. <https://pubmed.ncbi.nlm.nih.gov/32454035>
8. Sakurada Y, Fragiotta S, Leong BCS, Parikh R, Hussnain SA, Freund KB. **Relationship Between Choroidal Vascular Hyperpermeability, Choriocapillaris Flow Density, and Choroidal Thickness In Eyes with Pachychoroid Pigment Epitheliopathy.** *Retina.* 2020 Apr;40(4):657-662. <https://pubmed.ncbi.nlm.nih.gov/31415450/>
9. Sacconi R, Corbelli E, Borrelli E, Capone L, Carnevali A, Gelormini F, Querques L, Bandello F, Querques G. **Choriocapillaris Flow Impairment Could Predict the Enlargement of Geographic Atrophy Lesion.** *Br J Ophthalmol.* Epub 2020 Mar 22. <https://pubmed.ncbi.nlm.nih.gov/32201374>
10. Gendelman I, Alibhai AY, Moulton EM, Levine ES, Braun PX, Mehta N, Zhao Y, Ishibazawa A, Sorour OA, Baumal CR, Witkin AJ, Reichel E, Fujimoto JG, Duker JS, Waheed NK. **Topographic Analysis of Macular Choriocapillaris Flow Deficits In Diabetic Retinopathy Using Swept-Source Optical Coherence Tomography Angiography.** *Int J Retina Vitreous.* 2020 Mar 19;6:6. <https://pubmed.ncbi.nlm.nih.gov/32206342/>
11. Dai Y, Zhou H, Chu Z, Zhang Q, Chao JR, Rezaei KA, Wang RK. **Microvascular Changes in the Choriocapillaris of Diabetic Patients Without Retinopathy Investigated by Swept-Source OCT Angiography.** *IOVS.* 2020 Mar 9;61(3):50. <https://pubmed.ncbi.nlm.nih.gov/32232345/>
12. Zhou H, Dai Y, Gregori G, Rosenfeld PR, Duncan JL, Schwartz DM, Wang RK. **Automated Morphometric Measurement of the Retinal Pigment Epithelium Complex and Choriocapillaris Using Swept Source OCT.** *Biomed Opt Express.* 2020 Mar 6;11(4):1834-1850. <https://pubmed.ncbi.nlm.nih.gov/32341851/>
13. Yun C, Nam KT, Park S, Hwang SY, Oh. **Features of the Choriocapillaris On Four Different Optical Coherence Tomography Angiography Devices.** *J. Int Ophthalmol.* 2020 Feb;40(2):325-333. Epub 2019 Sep 28. <https://pubmed.ncbi.nlm.nih.gov/31564048>

14. Shi Y, Zhang Q, Zheng F, Russell JF, Motulsky EH, Banta JT, Chu Z, Zhou H, Patel NA, de Sisternes L, Durbin MK, Feuer W, Gregori G, Wang RK, Rosenfeld PJ. **Correlations Between Different Choriocapillaris Flow Deficit Parameters in Normal Eyes Using Swept Source OCT Angiography.** *Am J Ophthalmol.* 2020 Jan;209:18-26. <https://pubmed.ncbi.nlm.nih.gov/31562858/>
15. Chu Z, Gregori G, Rosenfeld PJ, Wang RK. **Quantification of Choriocapillaris With Optical Coherence Tomography Angiography: A Comparison Study.** *Am J Ophthalmol.* 2019 Dec;208:111-123. <https://pubmed.ncbi.nlm.nih.gov/31323202/>
16. Mastropasqua R, Viggiano P, Borrelli E, Evangelista F, Libertini D, Di Antonio L, Toto L. **In Vivo Mapping of the Choriocapillaris in High myopia: a Widefield Swept Source Optical Coherence Tomography Angiography.** *Sci Rep.* 2019 Dec 12;9(1):18932. <https://pubmed.ncbi.nlm.nih.gov/31831754>
17. Braun PX, Mehta N, Gendelman I, Alibhai AY, Moulton EM, Zhao Y, Ishibazawa A, Sorour O, Konstantinou EK, Baumal CR, Witkin AJ, Fujimoto JG, Duker JS, Waheed NK. **Global Analysis of Macular Choriocapillaris Perfusion in Dry Age-Related Macular Degeneration using Swept-Source Optical Coherence Tomography Angiography.** *IOVS.* 2019 Dec 2;60(15):4985-4990. <https://pubmed.ncbi.nlm.nih.gov/31791062>
18. Borrelli E, Uji A, Toto L, Viggiano P, Evangelista F, Mastropasqua R. **In Vivo Mapping of the Choriocapillaris in Healthy Eyes: A Widefield Swept-Source OCT Angiography Study.** *Ophthalmol Retina.* 2019 Nov;3(11):979-984. <https://pubmed.ncbi.nlm.nih.gov/31371198/>
19. Fernández-Avellaneda P, Breazzano MP, Fragiotta S, Xu X, Zhang Q, Wang RK, Freund KB. **Bacillary Layer Detachment Overlying Reduced Choriocapillaris Flow In Acute Idiopathic Maculopathy.** *Retin Cases Brief Rep.* Epub 2019 Nov 19. <https://pubmed.ncbi.nlm.nih.gov/31764886>
20. Sacconi R, Borrelli E, Corbelli E, Capone L, Rabiolo A, Carnevali A, Casaluci M, Gelormini F, Querques L, Bandello F, Querques G. **Quantitative Changes In the Ageing Choriocapillaris as Measured By Swept Source Optical Coherence Tomography Angiography.** *Br J Ophthalmol.* 2019 Sep;103(9):1320-1326. <https://pubmed.ncbi.nlm.nih.gov/30361273/>
21. Mastropasqua R, Senatore A, Di Antonio L, Di Nicola M, Marchioni M, Perna F, Amore F, Borrelli E, De Nicola C, Carpineto P, Toto L. **Correlation between Choriocapillaris Density and Retinal Sensitivity in Stargardt Disease.** *J Clin Med.* 2019 Sep 10;8(9):1432. <https://pubmed.ncbi.nlm.nih.gov/31510083/>
22. Rinella NT, Zhou H, Zhang Q, Keiner C, Oldenburg CE, Duncan JL, Wang RK, Schwartz DM. **Quantifying Choriocapillaris Flow Voids in Patients With Geographic Atrophy Using Swept-Source OCT Angiography.** *Ophthalmic Surg Lasers Imaging Retina.* 2019 Sep 1;50(9):e229-e235. <https://pubmed.ncbi.nlm.nih.gov/31589763/>
23. Keiner CM, Zhou H, Zhang Q, Wang RK, Rinella NT, Oldenburg CE, Duncan JL, Schwartz DM. **Quantifying Choriocapillaris Hypoperfusion In Patients with Choroidal Neovascularization Using Swept-Source OCT Angiography.** *Clin Ophthalmol.* 2019 Aug 26;13:1613-1620. <https://pubmed.ncbi.nlm.nih.gov/31692580/>
24. Tzaridis S, Wintergerst MWM, Mai C, Heeren TFC, Holz FG, Issa PC, Herrmann P. **Quantification of Retinal and Choriocapillaris Perfusion in Different Stages of Macular Telangiectasia Type 2.** *IOVS.* 2019 Aug 1;60(10):3556-3562. <https://pubmed.ncbi.nlm.nih.gov/31415079>
25. Nassisi M, Shi Y, Fan W, Borrelli E, Uji A, Ip MS, Sadda SR. **Choriocapillaris Impairment Around the Atrophic Lesions In Patients with Geographic Atrophy: A Swept-Source Optical Coherence Tomography Angiography Study.** *Br J Ophthalmol.* 2019 Jul;103(7):911-917. <https://pubmed.ncbi.nlm.nih.gov/30131381/>
26. Thulliez M, Zhang Q, Shi Y, Zhou H, Chu Z, de Sisternes L, Durbin MK, Feuer W, Gregori G, Wang RK, Rosenfeld PJ. **Correlations between Choriocapillaris Flow Deficits around Geographic Atrophy and Enlargement Rates Based on Swept-Source OCT Imaging.** *Ophthalmol Retina.* 2019 Jun;3(6):478-488. <https://pubmed.ncbi.nlm.nih.gov/31174669>

27. Zheng F, Zhang Q, Shi Y, Russell JF, Motulsky EH, Banta JT, Chu Z, Zhou H, Patel NA, de Sistiernes L, Durbin MK, Feuer W, Gregori G, Wang R, Rosenfeld PJ. **Age-dependent Changes in the Macular Choriocapillaris of Normal Eyes Imaged With Swept-Source Optical Coherence Tomography Angiography.** *Am J Ophthalmol.* 2019 Apr;200:110-122. <https://pubmed.ncbi.nlm.nih.gov/30639367/>
28. Chu Z, Zhang Q, Zhou H, Shi, Y, Zheng F, Gregori G, Rosenfeld PJ, Wang RK. **Quantifying Choriocapillaris Flow Deficits Using Global and Localized Thresholding Methods: A Correlation Study.** *Quant Imaging Med Surg.* 2018 Dec;8(11):1102-1112. <https://pubmed.ncbi.nlm.nih.gov/30701164/>
29. Borrelli E, Shi Y, Uji A, Balasubramanian S, Nassisi M, Sarraf D, Sadda SR. **Topographic Analysis of the Choriocapillaris in Intermediate Age-Related Macular Degeneration.** *Am J Ophthalmol.* 2018 Dec;196:34-43. <https://pubmed.ncbi.nlm.nih.gov/30118688/>
30. Tan B, Chua J, Barathi A, Baskaran M, Chan A, Lin E, Ang M, Klose G, Schmetterer L. **Quantitative Analysis of Choriocapillaris in Non-Human Primates Using Swept-Source Optical Coherence Tomography Angiography (Ss-OCTA).** *Biomed Opt Express.* 2018 Dec 21;10(1):356-371. <https://pubmed.ncbi.nlm.nih.gov/30775105/>
31. Nassisi M, Baghdasaryan E, Tepelus T, Asanad , Borrelli E, Sadda SR. **Topographic Distribution of Choriocapillaris Flow Deficits in Healthy Eyes.** *PLoS One.* 2018 Nov 15;13(11):e0207638. <https://pubmed.ncbi.nlm.nih.gov/30440050/>
32. Sugano Y, Sekiryu T, Furuta M, Tomita R, Shintake H, Maehara H, Ojima A. **Morphometrical Evaluation of the Choriocapillaris Imaged by Swept-Source Optical Coherence Tomography Angiography.** *Clin Ophthalmol.* 2018 Nov 5;12:2267-2276. <https://pubmed.ncbi.nlm.nih.gov/30464388/>
33. Zhang Q, Shi , Zhou H, Gregori G, Chu , Zheng F, Motulsky H, de Sistiernes L, Durbin M, Rosenfeld PJ, Wang RK. **Accurate Estimation of Choriocapillaris Flow Deficits Beyond Normal Intercapillary Spacing with Swept Source OCT Angiography.** *Quant Imaging Med Surg.* 2018 Aug;8(7):658-666. <https://pubmed.ncbi.nlm.nih.gov/30211033/>
34. Swaminathan SS, Shah P, Zheng F, Gregori G, Rosenfeld PJ. **Detection of Choriocapillaris Loss in Alport Syndrome with Swept-Source OCT Angiography.** *Ophthalmic Surg Lasers Imaging Retina.* 2018 Feb 1;49(2):138-141. <https://pubmed.ncbi.nlm.nih.gov/29443365/>
35. Zhang, Q, Zheng F, Motulsky EH, Gregori G, Chu , Chen L, Li C, de Sistiernes L, Durbin M, Rosenfeld PJ, Wang RK. **A Novel Strategy for Quantifying Choriocapillaris Flow Voids Using Swept-Source OCT Angiography.** *Invest Ophthalmol Vis Sci.* 2018 Jan 1;59(1):203-211. <https://pubmed.ncbi.nlm.nih.gov/29340648/>
36. Lauermann JL, Eter, N, Alten F. **Optical Coherence Tomography Angiography Offers New Insights into Choriocapillaris Perfusion.** *Ophthalmologica.* 2018 Jan;239(2-3):74-84. <https://pubmed.ncbi.nlm.nih.gov/29353272/>
37. Yannuzzi NA, Swaminathan SS, Zheng F, Miller A, Gregori , Davis JL, Rosenfeld PJ. **Swept-Source OCT Angiography Shows Sparing of the Choriocapillaris in Multiple Evanescent White Dot Syndrome.** *Ophthalmic Surg Lasers Imaging Retina.* 2017 Jan 1;48(1):69-74. <https://pubmed.ncbi.nlm.nih.gov/28060397/>

Choroid

1. Kim K, Yang J, Feuer W, Gregori G, Kim ES, Rosenfeld PJ, Yu S. **A Comparison Study of Polypoidal Choroidal Vasculopathy Imaged With Indocyanine Green Angiography and Swept Source OCT Angiography.** *Am J Ophthalmol. Case Rep.* 2020 Sep;217:240-251. <https://pubmed.ncbi.nlm.nih.gov/32445699>
2. Reich M, Boehringer D, Rothaus K, Cakir B, Bucher F, Daniel M, Lang SJ, Lagrèze WA, Agostini H, Lange C. **Swept-Source Optical Coherence Tomography Angiography Alleviates Shadowing Artifacts Caused by Subretinal Fluid.** *Int Ophthalmol.* 2020 Aug;40(8):2007-2016. <https://pubmed.ncbi.nlm.nih.gov/32333339/>
3. Terheyden JH, Wintergerst MWM, Pizarro C, Pfau M, Turski GN, Holz FG, Finger RP. **Retinal and Choroidal Capillary Perfusion Are Reduced in Hypertensive Crisis Irrespective of Retinopathy.** *Transl Vis Sci Technol.* 2020 Jul 29;9(8):42. <https://tvst.arvojournals.org/article.aspx?articleid=2770536>
<https://pubmed.ncbi.nlm.nih.gov/32855888/>
4. Amoroso F, Souied EH, Ansary MF, Astroz P, Mouallem-Bézière A, Pedinielli A, Miere A. **Optical Coherence Tomography Angiography Findings of Choroidal Neovascularization Secondary to Laser Injury: A Case Report.** *Am J Ophthalmol Case Rep.* 2020 Jun 2;19:100767. <https://pubmed.ncbi.nlm.nih.gov/32548336/>
5. Siggel R, Spital C, Lentzsch A, Liakopoulos S. **Comparison of Automated versus Manually Modified OCT Angiography En Face Slabs for Detection of Choroidal Neovascularization.** *Ophthalmol Retina.* 2020 May;4(5):471-480. <https://pubmed.ncbi.nlm.nih.gov/32245653/>
6. Fung AT, Waldstein SM, Gal-Or O, Pellegrini M, Preziosa C, Shields JA, Welch RJ, Dolz-Marco R, Sarraf D, Nagiel A, Lalane R, Jung JJ, Ghazi NG, Ramtohl P, Arnold JJ, Sakurada Y, Choudhry N, Balaratnasingam C, Freund KB, Shields CL. **Focal Scleral Nodule: A New Name for Solitary Idiopathic Choroiditis and Unifocal Helioid Choroiditis.** *Ophthalmology.* [Epub 2020 Apr 22] <https://pubmed.ncbi.nlm.nih.gov/32507351/>
7. Al-Khersan H, Russell JF, Shi Y, Sridhar J, Gregori G, Flynn HW, Rosenfeld PJ. **Wide Field Swept Source OCT Angiography of Multifocal Retinal and Choroidal Occlusions From Embolic Triamcinolone Acetonide.** *Am J Ophthalmol Case Rep.* 2020 Apr 14;18:100704. <https://pubmed.ncbi.nlm.nih.gov/32322753/>
8. Ogawa Y, Maruko I, Koizumi H, Iida T. **Quantification of Choroidal Vasculature By High-Quality Structure En Face Swept-Source Optical Coherence Tomography Images In Eyes With Central Serous Chorioretinopathy.** *Retina.* 2020 Mar;40(3):529-536. <https://pubmed.ncbi.nlm.nih.gov/30550530/>
9. Ogawa Y, Maruko I, Koizumi H, Iida T. **Quantification of Choroidal Vasculature by High-Quality Structure En Face Swept-Source Optical Coherence Tomography Images in Eyes with Central Serous Chorioretinopathy.** *Retina.* 2020 Mar;40(3):529-536. <https://pubmed.ncbi.nlm.nih.gov/30550530/>
10. Barikian A, Davis J, Gregori G, Rosenfeld P. **Wide field swept source OCT angiography in acute syphilitic placoid chorioretinitis.** *Am J Ophthalmol. Case Rep.* 2020 Mar 27;18:100678. <https://pubmed.ncbi.nlm.nih.gov/32274447/>
11. Lee MW, Park HJ, Shin YI, Lee WH, Lim HB, Kim JY. **Comparison of Choroidal Thickness Measurements Using Swept Source and Spectral Domain Optical Coherence Tomography In Pachychoroid Diseases.** *PLoS One.* 2020 Feb 26;15(2):e0229134. <https://pubmed.ncbi.nlm.nih.gov/32101541>
12. Brar M, Sharma M, Grewal SPS, Grewal DS. **Comparison of Wide-Field Swept Source Optical Coherence Tomography Angiography and Fundus Autofluorescence In Tubercular Serpiginous-Like Choroiditis.** *Indian J Ophthalmol.* 2020 Jan;68(1):106-211. <https://pubmed.ncbi.nlm.nih.gov/31856483/>
13. Mori H, Yamada H, Sato Y, Takahashi K. **Optical Coherence Tomographic Angiography and Ultra-Widefield Indocyanine Green Angiography of A Choroidal Macrovesel.** *Am J Ophthalmol Case Rep.* 2020 Jan 30;18:100612. <https://pubmed.ncbi.nlm.nih.gov/32083226/>

14. Tsuji S, Sekiryu T, Sugano Y, Ojima A, Kasai A, Okamoto M, Eifuku S. **Semantic Segmentation of the Choroid in Swept Source Optical Coherence Tomography Images for Volumetrics.** *Sci Rep.* 2020 Jan 23;10(1):1088. <https://pubmed.ncbi.nlm.nih.gov/31974487/>
15. Fujita A, Kataoka K, Takeuchi J, Nakano Y, Horiguchi E, Kaneko H, Ito Y, Terasaki H. **Diagnostic Characteristics of Polypoidal Choroidal Vasculopathy Based On B-Scan Swept-Source Optical Coherence Tomography Angiography and Its Interrater Agreement Compared with Indocyanine Green Angiography.** *Retina.* Epub 2020 Jan 20. <https://pubmed.ncbi.nlm.nih.gov/31971919>
16. Giorno P, Iacono P, Scarinci F, Di Renzo A, Varano M, Parravano M. **Microvasculature Changes of Myopic Choroidal Neovascularization and the Predictive Value of Feeder Vessel Disappearance after Ranibizumab Treatment Revealed Using Optical Coherence Tomography Angiography.** *Ophthalmologica.* 2020;243(4):263-270. Epub 2019 Dec 13. <https://pubmed.ncbi.nlm.nih.gov/31838464>
17. Sacconi R, Tomasso L, Corbelli E, Carnevali A, Querques L, Casati S, Bandello F, Querques G. **Early Response To the Treatment of Choroidal Neovascularization Complicating Central Serous Chorioretinopathy: A OCT-Angiography Study.** *Eye (Lond).* 2019 Nov;33(11):1809-1817. <https://pubmed.ncbi.nlm.nih.gov/31267094>
18. Sahoo NK, Mishra SB, Iovino C, Singh SR, Munk MR, Berger L, Peiretti E, Chhablani J. **Optical Coherence Tomography Angiography Findings In Cystoid Macular Degeneration Associated With Central Serous Chorioretinopathy.** *Br J Ophthalmol.* 2019 Nov;103(11):1615-1618. <https://pubmed.ncbi.nlm.nih.gov/30602447/>
19. Karst SG, Beiglboeck H, Scharinger R, Meyer EL, Mitsch C, Scholda C, Schmidt-Erfurth UM. **Retinal and Choroidal Perfusion Status in the Area of Laser Scars Assessed With Swept-Source Optical Coherence Tomography Angiography.** *Invest Ophthalmol Vis Sci.* 2019 Nov 1;60(14):4865-4871. <https://pubmed.ncbi.nlm.nih.gov/31747687/>
20. Schouten IM, Palkar AH, Bhende M. **Macular Vortex Vein with Choroidal Neovascularisation In Pathologic Myopia.** *Indian J Ophthalmol.* 2019 Oct;67(10):1717-1718. <https://pubmed.ncbi.nlm.nih.gov/31546529/>
21. Benillouche J, Astroz P, Ohayon A, Srour M, Amoroso F, Pedinielli A, Mouallem A, Souied EH. **Optical Coherence Tomography Angiography Imaging of Choroidal Neovascularization Secondary To Choroidal Rupture Treated By Intravitreal Ranibizumab.** *Retin Cases Brief Rep.* Epub 2019 Oct 24. <https://pubmed.ncbi.nlm.nih.gov/31652192/>
22. Sekiryu T, Sugano Y, Ojima A, Mori T, Furuta M, Okamoto M, Eifuku S. **Hybrid Three-Dimensional Visualization of Choroidal Vasculature Imaged by Swept-Source Optical Coherence Tomography.** *Transl Vis Sci Technol.* 2019 Oct 22;8(5):31. <https://pubmed.ncbi.nlm.nih.gov/31649830/>
23. Matsumoto H, Kishi S, Mukai R, Akiyama H. **Remodeling of Macular Vortex Veins In Pachychoroid Neovascularopathy.** *Sci Rep.* 2019 Oct 11;9(1):14689. <https://pubmed.ncbi.nlm.nih.gov/31605004/>
24. Bo Q, Yan Q, Shen M, Song M, Sun M, Yu Y, Rosenfeld PJ, Wang F, Sun X. **Appearance of Polypoidal Lesions in Patients With Polypoidal Choroidal Vasculopathy Using Swept-Source Optical Coherence Tomographic Angiography.** *JAMA Ophthalmol.* 2019 Jun 1;137(6):642-650. <https://pubmed.ncbi.nlm.nih.gov/30998817/>
25. Christian B, Mayss A, Hasse B, Eberhard R, Kohler P, Hasler P, Erb S, Hoffmann M, Barthelmes D, Zweifel SA. **Multimodal Imaging of Choroidal Lesions In Disseminated Mycobacterium Chimaera Infection After Cardiothoracic Surgery.** *Retina.* 2019 Mar;39(3):452-464. <https://pubmed.ncbi.nlm.nih.gov/29206759>
26. Puyo L, Paques M, Fink M, Sahel J-A, Atlan M. **Choroidal Vasculature Imaging with Laser Doppler Holography.** *Biomed Opt Express.* 2019 Jan 31;10(2):995-1012. <https://pubmed.ncbi.nlm.nih.gov/30800528/>
27. Rezkallah A, Kodjikian L, Abukhashabah A, Denis P, Mathis T. **Hypertensive Choroidopathy: Multimodal Imaging and the Contribution of Wide-Field Swept-Source OCT-Angiography.** *Am J Ophthalmol Case Rep.* 2019 Jan 9;13:131-135. <https://pubmed.ncbi.nlm.nih.gov/30705996/>

28. Iesato Y, Tanaka M, Murata M, Kitahara J, Hirano T, Kurenuma T, Yoshida N, Murata T. **Complete Regression of Branching Vascular Network in Polypoidal Choroidal Vasculopathy by Ranibizumab and Photodynamic Therapy.** *BMC Ophthalmol.* 2018 Nov 3;18(1):284. <https://pubmed.ncbi.nlm.nih.gov/30390650/>
29. Sakurada Y, Leong BCS, Parikh R, Fragiotta S, Freund KB. **Association between Choroidal Caverns and Choroidal Vascular Hyperpermeability in Eyes with Pachychoroid Diseases.** *Retina.* 2018 Oct;38(10):1977-1983. <https://pubmed.ncbi.nlm.nih.gov/30198969/>
30. Cornut T, Seguy C, Rougier MB, Delyfer MN, Morillon C, Korobelnik JF. **Multimodal Imaging in Multiple Traumatic Choroidal Ruptures.** *J Fr Ophthalmol.* 2018 Sep;41(7):676-678. <https://pubmed.ncbi.nlm.nih.gov/30166234/>
31. Dolz-Marco R, Glover JP, Gal-Or O, Litts KM, Messinger JD, Zhang Y, Cozzi M, Pellegrini M, Freund KB, Staurenghi G, Curcio CA. **Choroidal and Sub-Retinal Pigment Epithelium Caverns: Multimodal Imaging and Correspondence with Friedman Lipid Globules.** *Ophthalmology.* 2018 Aug;125(8):1287-1301. <https://pubmed.ncbi.nlm.nih.gov/29625839/>
32. Montorio D, Giuffre C, Misericocchi E, Modorati G, Sacconi R, Mercuri S, Querques L, Querques G, Bandello F. **Swept-Source Optical Coherence Tomography Angiography in Serpiginous Choroiditis.** *Br J Ophthalmol.* 2018 Jul;102(7):991-995. <https://pubmed.ncbi.nlm.nih.gov/28982952/>
33. Zucchiatti I, Sacconi R, Parravano MC, Costanzo E, Querques L, Montorio D, Bandello F, Querques G. **Eplerenone Versus Observation in the Treatment of Acute Central Serous Chorioretinopathy: A Retrospective Controlled.** *Ophthalmol Ther.* 2018 Jun;7(1):109-118. <https://pubmed.ncbi.nlm.nih.gov/29442283/>
34. Namavari A, Zheng F, Motulsky EH, de Oliveira Dias JR, Gregori G, Rosenfeld PJ. **Swept-Source OCT Angiography Identifies Choroidal Neovascularization Arising from a Choroidal Nevus.** *Ophthalmic Surg Lasers Imaging Retina.* 2018 May 1;49(5):360-363. <https://pubmed.ncbi.nlm.nih.gov/29772047/>
35. Carnevali A, Sacconi R, Corbelli E, Querques L, Bandello F, Querques G. **Choroidal Caverns: A Previously Unreported Optical Coherence Tomography Finding in Best Vitelliform Dystrophy.** *Ophthalmic Surg Lasers Imaging Retina.* 2018 Apr 1;49(4):284-287. <https://pubmed.ncbi.nlm.nih.gov/29664989/>
36. Dansingani KK, Gal-Or O, Sadda SR, Yannuzzi LA, Freund KB. **Understanding Aneurysmal Type 1 Neovascularization (Polypoidal Choroidal Vasculopathy): A Lesson in the Taxonomy of 'Expanded Spectra' - a Review.** *Clin Exp Ophthalmol.* 2018 Mar;46(2):189-200. <https://pubmed.ncbi.nlm.nih.gov/29178419/>
37. Zheng F, Gregori G, Schaal KB, Legarreta AD, Miller AR, Roisman L, Feuer WJ, Rosenfeld PJ. **Choroidal Thickness and Choroidal Vessel Density in Nonexudative Age-Related Macular Degeneration Using Swept-Source Optical Coherence Tomography Imaging.** *Invest Ophthalmol Vis Sci.* 2016 Nov 1;57(14):6256-6264. <https://pubmed.ncbi.nlm.nih.gov/27849311/>
38. Stein G, Zheng F, Tran AQ, Dias JR, Motulsky EH, Gregori G, Rosenfeld PJ. **Swept Source OCT Angiography of Polypoidal Choroidal Vasculopathy Using Boundary Layer Specific Segmentation.** *Invest Ophthalmol Vis Sci.* 2017 Jun;58(8):1698 <https://iovs.arvojournals.org/article.aspx?articleid=2637816>
39. Miller A, Zheng F, Schaal KB, Roisman L, Legarreta AD, Feuer W, Rosenfeld PJ, Gregori G. **Widefield Swept Source OCT Choroidal Thickness Maps and Choroidal Vessel Distribution in Eyes with Dry Age-Related Macular Degeneration.** *Invest Ophthalmol Vis Sci.* 2016 Sep;57(12):4942 <https://iovs.arvojournals.org/article.aspx?articleid=2563115>

Diabetic Retinopathy

1. Arya M, Sorour O, Chaudhri J, Alibhai Y, Waheed NK, Duker JS, Bauml CR. **Distinguishing Intraretinal Microvascular Abnormalities from Retinal Neovascularization Using Optical Coherence Tomography Angiography.** *Retina.* 2020 Sep;40(9):1686-1695. <https://pubmed.ncbi.nlm.nih.gov/31613839>
2. Pichi F, Smith SD, Abboud EB, Neri P, Woodstock E, Hay S, Levine E, Bauml CR. **Wide-field optical coherence tomography angiography for the detection of proliferative diabetic retinopathy.** *Graefes Arch Clin Exp Ophthalmol.* 2020 Sep;258(9):1901-1909. <https://pubmed.ncbi.nlm.nih.gov/32474692/>
3. Ito H, Ito Y, Kataoka K, Ueno S, Takeuchi J, Nakano Y, Fujita A, Horiguchi E, Kaneko H, Iwase T, Terasaki H. **Association Between Retinal Layer Thickness and Perfusion Status in Extramacular Areas in Diabetic Retinopathy.** *Am J Ophthalmol.* 2020 Jul;215:25-36. <https://pubmed.ncbi.nlm.nih.gov/32224103>
4. Hirano T, Hoshiyama K, Hirabayashi K, Wakabayashi M, Toriyama Y, Tokimitsu M, Murata T. **Vitreoretinal Interface Slab in OCT Angiography for Detecting Diabetic Retinal Neovascularization.** *Ophthalmol Retina.* 2020 Jun;4(6):588-594. <https://pubmed.ncbi.nlm.nih.gov/32107187>
5. Tian M, Wolf S, Munk MR, Schaal KB. **Evaluation of Different Swept-source Optical Coherence Tomography Angiography (SS-OCTA) Slabs for the Detection of Features Of Diabetic Retinopathy.** *Acta Ophthalmol.* 2020 Jun;98(4):e416-e420. <https://pubmed.ncbi.nlm.nih.gov/31663681>
6. Toto L, D'Aloisio R, Chiarelli AM, Di Antonio L, Evangelista F, D'Onofrio G, Merla A, Parravano M, Di Marzio G, Mastropasqua R. **A Custom-Made Semiautomatic Analysis of Retinal Nonperfusion Areas After Dexamethasone for Diabetic Macular Edema.** *Transl Vis Sci Technol.* 2020 Jun 11;9(7):13. <https://tvst.arvojournals.org/article.aspx?articleid=2766327>
<https://pubmed.ncbi.nlm.nih.gov/32832220>
7. Karst SG, Heisler M, Lo J, Schuck N, Safari A, Sarunic MV, Maberley DAL, Navajas EV. **Evaluating Signs of Microangiopathy Secondary to Diabetes in Different Areas of the Retina with Swept Source OCTA.** *Invest Ophthalmol Vis Sci.* 2020 May 11;61(5):8. <https://pubmed.ncbi.nlm.nih.gov/32392316/>
8. Heisler M, Karst S, Lo J, Mammo Z, Yu T, Warner S, Maberley D, Beg MF, Navajas EV, Sarunic MV. **Ensemble Deep Learning for Diabetic Retinopathy Detection Using Optical Coherence Tomography Angiography.** *Transl Vis Sci Technol.* 2020 Apr 13;9(2):20. <https://pubmed.ncbi.nlm.nih.gov/32818081/>
9. Alibhai AY, De Pretto LR, Moulton EM, Or C, Arya M, McGowan M, Carrasco-Zevallos O, Lee B, Chen S, Bauml CR, Witkin AJ, Reichel E, de Freitas AZ, Duker JS, Fujimoto JG, Waheed NK. **Quantification of Retinal Capillary Nonperfusion in Diabetics Using Wide-Field Optical Coherence Tomography Angiography.** *Retina.* 2020 Mar;40(3):412-420. <https://pubmed.ncbi.nlm.nih.gov/30576300/>
10. Khalid H, Schwartz R, Nicholson L, Huemer J, El-Bradey MH, Sim DA, Patel PJ, Balaskas K, Hamilton RD, Keane PA, Rajendram R. **Widefield Optical Coherence Tomography Angiography for Early Detection and Objective Evaluation of Proliferative Diabetic Retinopathy.** *Br J Ophthalmol.* Epub 2020 Mar 19. <https://pubmed.ncbi.nlm.nih.gov/32193221/>
11. Gendelman I, Alibhai AY, Moulton EM, Levine ES, Braun PX, Mehta N, Zhao Y, Ishibazawa A, Sorour OA, Bauml CR, Witkin AJ, Reichel E, Fujimoto JG, Duker JS, Waheed NK. **Topographic Analysis of Macular Choriocapillaris Flow Deficits in Diabetic Retinopathy Using Swept-Source Optical Coherence Tomography Angiography.** *Int J Retina Vitreous.* 2020 Mar 19;6:6. <https://pubmed.ncbi.nlm.nih.gov/32206342/>

12. Dai Y, Zhou H, Chu Z, Zhang Q, Chao JR, Rezaei KA, Wang RK. **Microvascular Changes in the Choriocapillaris of Diabetic Patients Without Retinopathy Investigated by Swept-Source OCT Angiography.** *Invest Ophthalmol Vis Sci.* 2020 Mar 9;61(3):50. <https://pubmed.ncbi.nlm.nih.gov/32232345/>
13. Parravano M, Costanzo E, Borrelli E, Sacconi R, Virgili G, Sadda SR, Scarinci F, Varano M, Bandello F, Querques G. **Appearance of Cysts and Capillary Non Perfusion Areas In Diabetic Macular Edema Using Two Different OCTA Devices.** *Sci Rep.* 2020 Jan 21;10(1):800. <https://pubmed.ncbi.nlm.nih.gov/31964977>
14. Tan B, Chua J, Lin E, Cheng J, Gan A, Yao X, Wong DWK, Sabanayagam C, Wong D, Chan CM, Wong TY, Schmetterer L, Tan GS. **Quantitative Microvascular Analysis with Wide-Field Optical Coherence Tomography Angiography in Eyes With Diabetic Retinopathy.** *JAMA Netw Open.* 2020 Jan 3;3(1):e1919469. <https://pubmed.ncbi.nlm.nih.gov/31951275/>
15. Schaal KB, Munk MR, Wyssmueller I, Berger LE, Zinkernagel MS, Wolf, S. **Vascular Abnormalities in Diabetic Retinopathy Assessed with Swept-Source Optical Coherence Tomography Angiography Widefield Imaging.** *Retina.* 2019;39(1):79 <https://www.ncbi.nlm.nih.gov/pubmed/29135803>
16. Hirano T, Kitahara J, Toriyama Y, Kasamatsu H, Murata T, Sadda S. **Quantifying Vascular Density and Morphology Using Different Swept-Source Optical Coherence Tomography Angiographic Scan Patterns in Diabetic Retinopathy.** *Br J Ophthalmol.* 2019;103(2):216 <https://www.ncbi.nlm.nih.gov/pubmed/29706601>
17. Couturier A, Rey PA, Erginay A, Lavia C, Bonnin S, Dupas B, Gaudric A, Tadayoni R. **Widefield OCT-Angiography and Fluorescein Angiography Assessments of Nonperfusion in Diabetic Retinopathy and Edema Treated with Anti-Vascular Endothelial Growth Factor.** *Ophthalmology.* 2019 Dec;126(12):1685-1694. <https://pubmed.ncbi.nlm.nih.gov/31383483>
18. Mastropasqua R, D'Aloisio R, Di Antonio L, Erroi E, Borrelli E, Evangelista F, D'Onofrio G, Di Nicola G10M, Di Martino G, Toto L. **Widefield Optical Coherence Tomography Angiography In Diabetic Retinopathy.** *Acta Diabetol.* 2019 Dec;56(12):1293-1303. <https://pubmed.ncbi.nlm.nih.gov/31468199/>
19. Borrelli E, Sacconi R, Brambati M, Bandello F, Querques G. **In Vivo Rotational Three-Dimensional OCTA Analysis of Microaneurysms In the Human Diabetic Retina.** *Sci Rep.* 2019 Nov 14;9(1):16789. <https://pubmed.ncbi.nlm.nih.gov/31728070>
20. Ishibazawa A, De Pretto LR, Alibhai AY, Moulton EM, Arya M, Sorour O, Mehta N, Baumal CR, Witkin AJ, Yoshida A, Duker JS, Fujimoto JG, Waheed NK. **Retinal Nonperfusion Relationship to Arteries or Veins Observed on Widefield Optical Coherence Tomography Angiography in Diabetic Retinopathy.** *Invest Ophthalmol Vis Sci.* 2019 Oct 1;60(13):4310-4318. <https://pubmed.ncbi.nlm.nih.gov/31622467>
21. Sacconi R, Casaluci M, Borrelli E, Mulinacci G, Lamanna F, Gelormini F, Carnevali A, Querques L, Zerbini G, Bandello F, Querques G. **Multimodal Imaging Assessment of Vascular and Neurodegenerative Retinal Alterations in Type 1 Diabetic Patients without Fundoscopic Signs of Diabetic Retinopathy.** *J Clin Med.* 2019 Sep 8;8(9):1409. <https://pubmed.ncbi.nlm.nih.gov/31500344>
22. Motulsky EH, Liu G, Shi Y, Zheng F, Flynn HW Jr, Gregori G, Rosenfeld PJ. **Widefield Swept-Source Optical Coherence Tomography Angiography of Proliferative Diabetic Retinopathy.** *Ophthalmic Surg Lasers Imaging Retina.* 2019 Aug 1;50(8):474-484. <https://pubmed.ncbi.nlm.nih.gov/31415693/>
23. Vujosevic S, Toma C, Villani E, Gatti V, Brambilla M, Muraca A, Ponziani MC, Aimaretti G, Nuzzo A, Nucci P, De Cilla' S. **Early Detection of Microvascular Changes in Patients with Diabetes Mellitus without and with Diabetic Retinopathy: Comparison between Different Swept-Source OCT-A Instruments.** *J Diabetes Res.* 2019 Jun 12;2019:2547216. <https://pubmed.ncbi.nlm.nih.gov/31281849>
24. Ashimatey BS, Green KM, Chu Z, Wang RK, Kashani AH. **Impaired Retinal Vascular Reactivity in Diabetic Retinopathy as Assessed by Optical Coherence Tomography Angiography.** *Invest Ophthalmol Vis Sci.* 2019 Jun 3;60(7):2468-2473. <https://pubmed.ncbi.nlm.nih.gov/31173077/>

25. Russell JF, Shi Y, Hinkle J, et al. **Longitudinal Wide-Field Swept-Source OCT Angiography of Neovascularization in Proliferative Diabetic Retinopathy after Panretinal Photocoagulation.** *Ophthalmol Retina.* 2019 Apr;3(4):350-61. [https://www.opthalmologyretina.org/article/S2468-6530\(18\)30604-3/fulltext](https://www.opthalmologyretina.org/article/S2468-6530(18)30604-3/fulltext)
26. Breazzano MP, Fernández-Avellaneda P, Freund KB. **Swept-Source Optical Coherence Tomography Angiography of Retinal Arterial Macroaneurysm With Overlying Hemorrhage.** *JAMA Ophthalmol.* 2019 Apr 1;137(4):e190247 <https://www.ncbi.nlm.nih.gov/pubmed/30973588>
27. Schaal KB, Munk MR, Wyssmueller I, Berger L, Zinkernagel MS, Wolf S. **Vascular Abnormalities in Diabetic Retinopathy Assessed with Swept-Source Optical Coherence Tomography Angiography Widefield Imaging.** *Retina.* 2019 Jan;39(1):79-87 <https://www.ncbi.nlm.nih.gov/pubmed/29135803>
28. Zhang Q, Rezaei KA, Saraf SS, Chu Z, Wang F, Wang RK. **Ultra-Wide Optical Coherence Tomography Angiography in Diabetic Retinopathy.** *Quant Imaging Med Surg.* 2018;8(8):743 <https://www.ncbi.nlm.nih.gov/pubmed/30306055>
29. Yasukura S, Murakami T, Suzuma K, Yoshitake T, Nakanishi H, Fujimoto M, Oishi M, Tsujikawa A. **Diabetic Nonperfused Areas in Macular and Extramacular Regions on Wide-Field Optical Coherence Tomography Angiography.** *Invest Ophthalmol Vis Sci.* 2018;59(15):5893 <https://www.ncbi.nlm.nih.gov/pubmed/30550612>
30. Shroff D, Gupta P, Gupta C, Shroff C. **Post-Laser Regression of Diabetic Neovascularization: An Optical Coherence Tomography Angiography Study.** *Indian J Ophthalmol.* 2018;66(12):1855 <https://www.ncbi.nlm.nih.gov/pubmed/30451198>
31. Sawada O, Ichiyama Y, Obata S, Ito Y, Kakinoki M, Sawada T, Saishin Y, Ohji M. **Comparison between Wide-Angle OCT Angiography and Ultra-Wide Field Fluorescein Angiography for Detecting Non-Perfusion Areas and Retinal Neovascularization in Eyes with Diabetic Retinopathy.** *Graefes Arch Clin Exp Ophthalmol.* 2018;256(7):1275 <https://www.ncbi.nlm.nih.gov/pubmed/29713816>
32. Fenner BJ, Wong RLM, Lam WC, Tan GSW, Cheung GCM. **Advances in Retinal Imaging and Applications in Diabetic Retinopathy Screening: A Review.** *Ophthalmol Ther.* 2018;7(2):333 <https://www.ncbi.nlm.nih.gov/pubmed/30415454>
33. Korobelnik JF, Rougier MB, Delyfer MN. **[Wide Field OCT-Angiography of a Patient with Proliferative Diabetic Retinopathy].** [Article in French] *J Fr Ophthalmol.* 2017;40(8):721 <https://www.ncbi.nlm.nih.gov/pubmed/28912061>
34. Sawada O, Ichiyama Y, Ito Y, Kakinoki M, Sawada T, Saishin Y, Ohji M. **Comparison between Wide Angle OCT Angiography and Ultra-Wide Field Fluorescein Angiography on the Detection of Non-Perfusion Area.** *Invest Ophthalmol Vis Sci.* 2017 Jun;58(8):1700 <https://iovs.arvojournals.org/article.aspx?articleid=2639517&resultClick=1>
35. Kwon JY, Kashani AH, Liu G, Zheng F, Miller A, Chu Z, Wang RK, Gregori G, Rosenfeld PJ. **Suspended Scattering Particles in Motion (Sspim): A Feature of OCT Angiography in Diabetic Macular Edema.** *Invest Ophthalmol Vis Sci.* 2017 Jun;58(8):937 <https://iovs.arvojournals.org/article.aspx?articleid=2638014&resultClick=1>
36. Zhang Q, Chen CL, Attaran-Rezaei K, Wang RK. **Ultra-Wide Field Optical Coherence Tomography Angiography for Evaluation of Diabetic Retinopathy.** *Invest Ophthalmol Vis Sci.* 2017 Jun;58(8):5447 <https://iovs.arvojournals.org/article.aspx?articleid=2638241&resultClick=1>
37. Cheng S, Leng T. **Noninvasive Detection of Microaneurysms in Diabetic Retinopathy by Swept-Source Optical Coherence Tomography.** *Clin Ophthalmol.* 2016;10:1791 <https://www.ncbi.nlm.nih.gov/pubmed/27695284>
38. Shahidzadeh A, Kim AY, Aziz HA, Durbin MK, Puliafito C, Kashani AH. **Widefield Swept-Source Optical Coherence Tomography Angiography.** *Invest Ophthalmol Vis Sci.* 2016 Sep;57(12):445 <https://iovs.arvojournals.org/article.aspx?articleid=2558091&resultClick=1>
39. Matsunaga D, Yi J, Olmos LC, Legarreta J, Legarreta AD, Gregori G, Sharma A, Rosenfeld, PJ, Puliafito, C, Kashani, AH. **OCT Angiography (OCTA) of Diabetic Retinopathy.** *Invest Ophthalmol Vis Sci.* 2015 Jun;56(7):3335. <https://iovs.arvojournals.org/article.aspx?articleid=2333192&resultClick=1>

Glaucoma and Optic Neuropathies

1. Mursch-Edlmayr AS, Waser K, Podkowinski D, Bolz M. **Differences In Swept-Source OCT Angiography of the Macular Capillary Network In High Tension and Normal Tension Glaucoma.** *Curr Eye Res.* 2020 Sep;45(9):1168-1172. <https://pubmed.ncbi.nlm.nih.gov/32011184/>
2. Bojjikian KD, Nobrega P, Wen JC, Zhang Q, Mudumbai RC, Johnstone MA, Wang RK, Chen PP. **Macular Vascular Microcirculation in Eyes With Open-angle Glaucoma Using Different Visual Field Severity Classification Systems.** *J Glaucoma.* 2019 Sep;28(9):790-796. <https://pubmed.ncbi.nlm.nih.gov/31233458>
3. Tan B, Chua J, Harish T, Lau A, Gan ATL, Tan YL, Wong DWK, Chong RS, Ang M, Husain R, Schmetterer L. **Comparison of A Commercial Spectral-Domain OCT And Swept-Source OCT Based On an Angiography Scan for Measuring Circumpapillary Retinal Nerve Fibre Layer Thickness.** *Br J Ophthalmol.* 2020 Jul;104(7):974-979. <https://pubmed.ncbi.nlm.nih.gov/31585965>
4. Tepelus TC, Song S, Borrelli E, Nittala MG, Baghdasaryan E, Sadda SR, Chopra V. **Quantitative Analysis of Retinal and Choroidal Vascular Parameters in Patients With Low Tension Glaucoma.** *J Glaucoma.* 2019 Jun;28(6):557-562. <https://pubmed.ncbi.nlm.nih.gov/30889061>
5. Sousa, DC, Sacconi, R, Bandello, F, Querques, G. **Scleral Cyst Associated with Anomalous Tilted Configuration of the Optic Nerve Head: A Case Report.** *Ophthalmol Ther.* 2019 Mar;8(1):149-53 <https://www.ncbi.nlm.nih.gov/pubmed/30739279>
6. Rougier, MB, Le Goff, M, Korobelnik, JF. **Optical Coherence Tomography Angiography at the Acute Phase of Optic Disc Edema.** *Eye Vis (Lond).* 2018 Jun;5:15 <https://www.ncbi.nlm.nih.gov/pubmed/29977949>
7. Triolo, G, Rabiolo, A, Shemonski, ND, Fard, A, Di Matteo, F, Sacconi, R, Bettin, P, Magazzeni, S, Querques, G, Vazquez, LE, Barboni, P, Bandello, F. **Optical Coherence Tomography Angiography Macular and Peripapillary Vessel Perfusion Density in Healthy Subjects, Glaucoma Suspects, and Glaucoma Patients.** *Invest Ophthalmol Vis Sci.* 2017 Nov;58(13):5713-22 <https://www.ncbi.nlm.nih.gov/pubmed/29114838>
<https://iovs.arvojournals.org/article.aspx?articleid=2661826>
8. Chen, C-L, Nobrega, P, Wen, JC, Mudumbai, R, Menda, S, Johnstone, M, Chen, PP, Wang, RK. **Microvasculature Changes in Macular Region in Glaucomatous Eyes Using Optical Coherence Tomography-Based Angiography (OCTA).** *Invest Ophthalmol Vis Sci.* 2017 Jun;58(8):1677 <https://iovs.arvojournals.org/article.aspx?articleid=2637414&resultClick=1>
9. Blaesi, JM, Shemonski, N, Straub, J. **Quantification of Retinal Blood Flow Using Doppler OCT with a Plex™ Elite 9000.** *Invest Ophthalmol Vis Sci.* 2017 Jun;58(8):726 <https://iovs.arvojournals.org/article.aspx?articleid=2638574&resultClick=1>
10. Triolo, G, Rabiolo, A, Galasso, M, De Vitis, L, Sacconi, R, Di Matteo, F, Bettin, P, Barboni, P, Querques, G, Bandello, F, vazquez, LE. **Assessment of Peripapillary and Macular Vessel Density Estimated with OCT-Angiography in Glaucoma Suspects and Glaucoma Patients.** *Invest Ophthalmol Vis Sci.* 2017 Jun;58(8):715 <https://iovs.arvojournals.org/article.aspx?articleid=2638812&resultClick=1>
11. Srinivas, S, Dastiridou, A, Durbin, MK, Nittala, MG, Huang, AA, Tan, JC, Francis, BA, Sadda, SR, Chopra, V. **Pilot Study of Lamina Cribrosa Intensity Measurements in Glaucoma Using Swept-Source Optical Coherence Tomography.** *J Glaucoma.* 2017 Feb;26(2):138-43 <https://www.ncbi.nlm.nih.gov/pubmed/27977479>
<https://insights.ovid.com/pubmed?pmid=27977479>

Healthy Subjects

1. Byon I, Alagorie AR, Ji Y, Su L, Sadda SR. **Optimizing the Repeatability of Choriocapillaris Flow Deficit Measurement from Optical Coherence Tomography Angiography.** *Am J Ophthalmol.* 2020 May 23;219:21-32. <https://pubmed.ncbi.nlm.nih.gov/32454035>
2. Minami S, Ito Y, Ueno S, Kataoka K, Takeuchi J, Ito H, Nakano Y, Kitagawa M, Leahy C, Straub J, Terasaki H. **Analysis of Macular Curvature in Normal Eyes Using Swept-Source Optical Coherence Tomography.** *Jpn J Ophthalmol.* 2020 Mar;64(2):180-186. <https://pubmed.ncbi.nlm.nih.gov/32040660/>
3. Borrelli E, Toto L, Viggiano P, Evangelista F, Palmieri M, Mastropasqua R. **Widefield Topographical Analysis of the Retinal Perfusion and Neuroretinal Thickness In Healthy Eyes: A Pilot Study.** *Eye (Lond).* Epub 2020 Feb 13. <https://pubmed.ncbi.nlm.nih.gov/32055020/>
4. Shi Y, Zhang Q, Zheng F, Russell JF, Motulsky EH, Banta JT, Chu Z, Zhou H, Patel NA, de Sisternes L, Durbin MK, Feuer W, Gregori G, Wang RK, Rosenfeld PJ. **Correlations Between Different Choriocapillaris Flow Deficit Parameters in Normal Eyes Using Swept Source OCT Angiography.** *Am J Ophthalmol.* 2020 Jan;209:18-26. <https://pubmed.ncbi.nlm.nih.gov/31562858/>
5. Borrelli E, Uji A, Toto L, Viggiano P, Evangelista F, Mastropasqua R. **In Vivo Mapping of the Choriocapillaris in Healthy Eyes: A Widefield Swept-Source OCT Angiography Study.** *Ophthalmol Retina.* 2019 Nov;3(11):979-984. <https://pubmed.ncbi.nlm.nih.gov/31371198/>
6. Eastline M, Munk MR, Wolf S, Schaal KB, Ebnetter A, Tian M, Giannakaki-Zimmermann H, Zinkernagel MS. **Repeatability of Wide-field Optical Coherence Tomography Angiography in Normal Retina.** *Transl Vis Sci Technol.* 2019 May 2;8(3):6. <https://pubmed.ncbi.nlm.nih.gov/31106033>
7. Zheng F, Zhang Q, Shi Y, Russell JF, Motulsky EH, Banta JT, Chu Z, Zhou H, Patel NA, de Sisternes L, Durbin MK, Feuer W, Gregori G, Wang R, Rosenfeld PJ. **Age-dependent Changes in the Macular Choriocapillaris of Normal Eyes Imaged With Swept-Source Optical Coherence Tomography Angiography.** *Am J Ophthalmol.* 2019 Apr;200:110-122. <https://pubmed.ncbi.nlm.nih.gov/30639367/>
8. Zhou H, Chu Z, Zhang Q, Dai Y, Gregori G, Rosenfeld PJ, Wang RK. **Attenuation Correction Assisted Automatic Segmentation for Assessing Choroidal Thickness and Vasculature with Swept-Source OCT.** *Biomed Opt Express.* 2018;9(12):6067-80 <https://www.osapublishing.org/boe/abstract.cfm?uri=boe-9-12-6067>
9. Akagi T, Uji A, Huang AS, Weinreb RN, Yamada T, Miyata M, Kameda T, Ikeda HO, Tsujikawa A. **Conjunctival and Intrascleral Vasculatures Assessed Using Anterior Segment Optical Coherence Tomography Angiography in Normal Eyes.** *Am J Ophthalmol.* 2018 Dec;196:1-9 <https://www.ncbi.nlm.nih.gov/pubmed/30099035>
10. Shoji T, Yoshikawa Y, Kanno J, Ishii H, Ibuki H, Ozaki K, Kimura I, Shinoda K. **Reproducibility of Macular Vessel Density Calculations Via Imaging with Two Different Swept-Source Optical Coherence Tomography Angiography Systems.** *Transl Vis Sci Technol.* 2018 Dec 21;7(6):31 <https://www.ncbi.nlm.nih.gov/pubmed/30619651>
11. Nassisi M, Baghdasaryan E, Tepelus , Asanad S, Borrelli E, Sadda SR. **Topographic Distribution of Choriocapillaris Flow Deficits in Healthy Eyes.** *PLoS One.* 2018 Nov 15;13(11):e0207638 <https://www.ncbi.nlm.nih.gov/pubmed/30440050>
12. Chu Z, Zhou H, Cheng Y, Zhang Q, Wang RK. **Improving Visualization and Quantitative Assessment of Choriocapillaris with Swept-Source OCTA through Registration and Averaging Applicable to Clinical Systems.** *Sci Rep.* 2018 Nov 14;8(1) <https://www.nature.com/articles/s41598-018-34826-5>

13. Sugano Y, Sekiryu T, Furuta M, Tomita R, Shintake H, Maehara H, Ojima A. **Morphometrical Evaluation of the Choriocapillaris Imaged by Swept-Source Optical Coherence Tomography Angiography.** *Clin Ophthalmol.* 2018 Nov 5;12:2267-76 <https://www.ncbi.nlm.nih.gov/pubmed/30464388>
14. Maruko I, Kawano T, Arakawa , Hasegawa T, Iida T. **Visualizing Large Choroidal Blood Flow by Subtraction of the Choriocapillaris Projection Artifacts in Swept-Source Optical Coherence Tomography Angiography in Normal Eyes.** *Sci Rep.* 2018 Oct 24;8(1):15694 <https://www.ncbi.nlm.nih.gov/pubmed/30356090>
15. Arya M, Rebhun CB, Alibhai Y, Chen X, Moreira-Neto C, Bauml CR, Reichel E, Witkin AJ, Duker JS, Sadda SR, Waheed NK. **Parafoveal Retinal Vessel Density Assessment by Optical Coherence Tomography Angiography in Healthy Eyes.** *Ophthalmic Surg Lasers Imaging Retina.* 2018 Oct 15;49(10):S5-17 <https://www.ncbi.nlm.nih.gov/pubmed/30339262>
16. Zhang Q, Shi Y, Zhou H, Gregori G, Chu Z, Zheng F, Motulsky EH, de Sisternes L, Durbin M, Rosenfeld J, Wang RK. **Accurate Estimation of Choriocapillaris Flow Deficits Beyond Normal Intercapillary Spacing with Swept-Source OCT Angiography.** *Quant Imaging Med Surg.* 2018 Aug;8(7):658-66 <https://www.ncbi.nlm.nih.gov/pubmed/30211033>
17. Wang F, Zhang Q, Deegan AJ, Chang J, Wang RK. **Comparing Imaging Capabilities of Spectral Domain and Swept-Source Optical Coherence Tomography Angiography in Healthy Subjects and Central Serous Retinopathy.** *Eye Vis (Lond).* 2018 Aug 8;5:19 <https://www.ncbi.nlm.nih.gov/pubmed/30094272>
18. Corvi F, Pellegrini M, Erba S, Cozzi M, Staurenghi G, Giani A. **Reproducibility of Vessel Density, Fractal Dimension, and Foveal Avascular Zone Using 7 Different Optical Coherence Tomography Angiography Devices.** *Am J Ophthalmol.* 2018 Feb;186:25-31 <https://www.ncbi.nlm.nih.gov/pubmed/29169882>
19. Mehta N, Zahid S, Chiu BQ, Bhardwa S, Tsui E, Young E, Young JA, Jung JJ. **Refinement of Fractal Analysis Methodology of Swept-Source Optical Coherence Tomography Angiography Images of Normal Eyes.** *Invest Ophthalmol Vis Sci.* 2017 Jun;58(8):1675 <https://iovs.arvojournals.org/article.aspx?articleid=2639505&resultClick=1>
20. Coffey VC. **Advanced OCT: Making Waves in the Market.** *Opt Photonics News.* 2016;27(9):26-33 <https://www.osapublishing.org/opn/abstract.cfm?uri=opn-27-9-26>
21. Straub J, Leahy C, Luu JY. **Wide-Field Swept-Source OCT En-Face Image Montages in Healthy Eyes.** *Invest Ophthalmol Vis Sci.* 2016 Sep;57(12):441 <http://iovs.arvojournals.org/article.aspx?articleid=2557941&resultClick=1>
22. Luu JY, Sha P, Durbin M. **Comparison of Spectral-Domain and Swept-Source Optical Coherence Tomography Choroidal Thickness Measurements in Normal Eyes.** *Invest Ophthalmol Vis Sci.* 2016 Sep;57(12):2178 <https://iovs.arvojournals.org/article.aspx?articleid=2560681&resultClick=1>
23. Gregori G, Rosenfeld PJ, Roisman L, Schaal KB. **Automated Retinal Segmentation for Widefield OCT, with Applications to OCT Angiography.** *Invest Ophthalmol Vis Sci.* 2016 Sep;57(12):446 <https://iovs.arvojournals.org/article.aspx?articleid=2559294&resultClick=1>
24. Yi J, Matsunaga D, Legarreta JE, Legarreta AD, Gregori G, Durbin M, Sharma A, Rosenfeld PJ, Puliafito C, Kashani AH. **OCT Angiography (OCTA) in Healthy Human Subjects.** *Invest Ophthalmol Vis Sci.* 2015 Jun;56(7):3318 <https://iovs.arvojournals.org/article.aspx?articleid=2333173&resultClick=1>
25. Kuehlewein L, Tepelus TC, An L, Durbin MK, Srinivas S, Sadda SR. **Noninvasive Visualization and Analysis of the Human Parafoveal Capillary Network Using Swept-Source OCT Optical Microangiography.** *Invest Ophthalmol Vis Sci.* 2015 Jun;56(6):3984-8 <https://www.ncbi.nlm.nih.gov/pubmed/26087363>
<https://iovs.arvojournals.org/article.aspx?articleid=2337491>
26. Huang Y, Zhang Q, Thorell MR, An L, Durbin MK, Laron M, Sharma U, Gregori G, Rosenfeld PJ, Wang RK. **Swept-Source OCT Angiography of the Retinal Vasculature Using Intensity Differentiation-Based Optical Microangiography Algorithms.** *Ophthalmic Surg Lasers Imaging Retina.* 2014 Sep-Oct;45(5):382-89 <https://www.ncbi.nlm.nih.gov/pmc/articles/PMC4286454/>
<https://www.ncbi.nlm.nih.gov/pmc/articles/PMC4286454/pdf/nihms648133.pdf>

Inflammation

1. Chu Z, Weinstein JE, Wang RK, Pepple KL. **Quantitative Analysis of the Choriocapillaris in Uveitis Using en face Swept Source Optical Coherence Tomography Angiography.** *Am J Ophthalmol.* 2020 Oct;218:17-27. <https://pubmed.ncbi.nlm.nih.gov/32413411>
2. Vingopoulos F, Cui Y, Katz R, Le R, Zhu Y, Wang JC, Lu Y, Sobrin L, Miller JB. **Widefield Swept-Source OCTA in Vogt-Koyanagi-Harada Disease Ophthalmic Surg Lasers Imaging.** *Retina.* 2020 Jul 1;51(7):407-412. <https://pubmed.ncbi.nlm.nih.gov/32706899/>
3. Pichi F, Smith SD, Neri P, Woodstock E, Hay S, Parrulli S, Corvi F, Mapelli C, Invernizzi A. **Choroidal Granulomas Visualized By Swept-Source Optical Coherence Tomography Angiography.** *Retina.* Epub 2020 May 27. <https://pubmed.ncbi.nlm.nih.gov/32467485/>
4. Accorinti M, Gilardi M, De Geronimo D, Iannetti L, Giannini D, Parravano M. **Optical Coherence Tomography Angiography Findings in Active and Inactive Ocular Behçet Disease.** *Ocul Immunol Inflamm.* 2020 May 18;28(4):589-600. <https://pubmed.ncbi.nlm.nih.gov/31560572>
5. Russell JF, Pichi F, Scott NL, Hartley MJ, Bell D, Agarwal A, Leong B, Holland GN, Freund KB, Sarraf D. **Masqueraders of multiple evanescent white dot syndrome (MEWDS).** *Int Ophthalmol.* 2020 Mar;40(3):627-638. <https://pubmed.ncbi.nlm.nih.gov/31792848/>
6. Barikian A, Davis J, Gregori G, Rosenfeld P. **Wide field swept source OCT angiography in acute syphilitic placoid chorioretinitis.** *Am J Ophthalmol.* 2020 Mar 27;18:100678. <https://pubmed.ncbi.nlm.nih.gov/32274447/>
7. Brar M, Sharma M, Grewal SPS, Grewal DS. **Comparison of Wide-Field Swept Source Optical Coherence Tomography Angiography and Fundus Autofluorescence In Tubercular Serpiginous-Like Choroiditis Indian.** *J Ophthalmol.* 2020 Jan;68(1):106-211. <https://pubmed.ncbi.nlm.nih.gov/31856483>
8. Tian M, Tappeiner C, Zinkernagel MS, Huf W, Wolf S, Munk MR. **Evaluation of Vascular Changes In Intermediate Uveitis and Retinal Vasculitis Using Swept-Source Wide-Field Optical Coherence Tomography Angiography.** *Br J Ophthalmol.* 2019 Sep;103(9):1289-1295. <https://pubmed.ncbi.nlm.nih.gov/30538102/>
9. Tian M, Tappeiner C, Zinkernagel MS, Wolf S, Munk MR. **Swept-Source Optical Coherence Tomography Angiography Reveals Vascular Changes In Intermediate Uveitis.** *Acta Ophthalmol.* 2019 Aug;97(5):e785-e791. <https://pubmed.ncbi.nlm.nih.gov/30729711>
10. Invernizzi A, Cozzi M, Staurengi G. **Optical Coherence Tomography and Optical Coherence Tomography Angiography In Uveitis: A Review.** *Clin Exp Ophthalmol.* 2019 Apr;47(3):357-371. <https://pubmed.ncbi.nlm.nih.gov/30719788>
11. Wintergerst, MWM, Pfau, M, Muller, PL, Berger, M, de Sisternes, L, Holz, FG, Finger, RP. **Optical Coherence Tomography Angiography in Intermediate Uveitis.** *Am J Ophthalmol.* 2018 Oct;194:35 <https://www.ncbi.nlm.nih.gov/pubmed/30026083>
12. Pakzad-Vaezi, K, Khaksari, K, Chu, Z, Van Gelder, RN, Wang, RK, Pepple, KL. **Swept-Source OCT Angiography of Serpiginous Choroiditis.** *Ophthalmol Retina.* 2018 Jul;2(7):712 <https://www.ncbi.nlm.nih.gov/pubmed/30148243>
13. Zicarelli F, Mantovani A, Preziosa C, Staurengi G. **Multimodal Imaging of Multiple Evanescent White Dot Syndrome: A New Interpretation.** *Ocul Immunol Inflamm.* 2020 Jul 3;28(5):814-820. <https://pubmed.ncbi.nlm.nih.gov/31414928>
14. Rodriguez, M, Gregori, NZ, Roisman, L, Lam, BL, Rosenfeld, PJ. **Swept-Source OCT Imaging of the Argus Ii Epiretinal Prosthesis.** *Ophthalmol Retina.* 2018 Apr;2(4):380-82 [https://www.opthalmologyretina.org/article/S2468-6530\(17\)30458-X/fulltext](https://www.opthalmologyretina.org/article/S2468-6530(17)30458-X/fulltext)

15. Swaminathan, SS, Zheng, F, Miller, AR, Gregori, G, Davis, JL, Rosenfeld, PJ. **Swept-Source OCT Angiography of Multiple Evanescent White Dot Syndrome with Inflammatory Retinal Pigment Epithelial Detachment.** *Ophthalmic Surg Lasers Imaging Retina*. 2018 Feb;49(2):145 <https://www.ncbi.nlm.nih.gov/pubmed/29443367>
16. Zahid, S, Chen, KC, Jung, JJ, Balaratnasingam, C, Ghadiali, Q, Sorenson, J, Rofagha, S, Freund, KB, Yannuzzi, LA. **Optical Coherence Tomography Angiography of Chorioretinal Lesions Due to Idiopathic Multifocal Choroiditis.** *Retina*. 2017 Aug;37(8):1451-63 <https://www.ncbi.nlm.nih.gov/m/pubmed/27880741>
http://journals.lww.com/retinajournal/Citation/2017/08000/OPTICAL_COHERENCE_TOMOGRAPHY_ANGIOGRAPHY_OF.4.aspx
<https://insights.ovid.com/pubmed?pmid=27880741>
17. Montorio, D, Giuffre, C, Miserocchi, E, Modorati, G, Sacconi, R, Mercuri, S, Querques, L, Querques, G, Bandello, F. **Swept-Source Optical Coherence Tomography Angiography in Serpiginous Choroiditis.** *Br J Ophthalmol*. 2017 Jul;102(7):991-95 <https://www.ncbi.nlm.nih.gov/pubmed/28982952>
<http://bjo.bmj.com/content/early/2017/10/05/bjophthalmol-2017-310989.long>
18. Khaksari, K, Pakzad-Vaezi, K, Pepple, KL, Wang, RK. **Optical Coherence Tomography Based-Microangiography of Macular Edema in Uveitis.** *Invest Ophthalmol Vis Sci*. 2017 Jun;58(8):526
<https://iovs.arvojournals.org/article.aspx?articleid=2638689&resultClick=1>
19. Finger, RP, Wintergerst, M, Holz, FG. **Swept-Source Optical Coherence Tomography Angiography Findings in Uveitis: Novel Biomarkers for Disease Activity?** *Invest Ophthalmol Vis Sci*. 2017 Jun;58(8):1885
<https://iovs.arvojournals.org/article.aspx?articleid=2639659&resultClick=1>
20. Chu, Z, Pepple, KL, Wang, RK. **Quantitative Analysis of Choriocapillaris in Uveitic and Normal Subjects with SS-OCT Angiography.** *Invest Ophthalmol Vis Sci*. 2017 Jun;58(8):1871
<https://iovs.arvojournals.org/article.aspx?articleid=2638333&resultClick=1>
21. Yannuzzi NA, Swaminathan SS, Zheng F, Miller A, Gregori G, Davis JL, Rosenfeld PJ. **Swept-Source OCT Angiography Shows Sparing of the Choriocapillaris in Multiple Evanescent White Dot Syndrome.** *Ophthalmic Surg Lasers Imaging Retina*. 2017 Jan 1;48(1):69-74. <https://pubmed.ncbi.nlm.nih.gov/28060397/>

Myopia

1. Giorno P, Iacono P, Scarinci F, Di Renzo A, Varano M, Parravano M. **Microvasculature Changes of Myopic Choroidal Neovascularization and the Predictive Value of Feeder Vessel Disappearance after Ranibizumab Treatment Revealed Using Optical Coherence Tomography Angiography.** *Ophthalmologica.* 2020;243(4):263-270. <https://pubmed.ncbi.nlm.nih.gov/31838464>
2. Breher K, Ohlendorf A, Wahl S. **Myopia Induces Meridional Growth Asymmetry of the Retina: A Pilot Study Using Wide-Field Swept-Source OCT.** *Sci. Rep.* 2020 Jul 2;10(1):10886. <https://pubmed.ncbi.nlm.nih.gov/32616797/>
3. Su L, Ji YS, Tong N, Sarraf D, He X, Sun X, Xu X, Sadda SR. **Quantitative Assessment of the Retinal Microvasculature and Choriocapillaris In Myopic Patients Using Swept-Source Optical Coherence Tomography Angiography.** *Graefes Arch Clin Exp Ophthalmol.* 2020 Jun;258(6):1173-1180. <https://pubmed.ncbi.nlm.nih.gov/32144487/>
4. Zheng F, Wong CW, Sabanayagam C, Cheung YB, Matsumura S, Chua J, Man REK, Ohno-Matsui K, Wong TY, Cheng CY, Tai ES, Lamoureux ELED, Schmetterer L, Kuo A, Hoang QV, Saw SM. **Prevalence, Risk Factors and Impact of Posterior Staphyloma Diagnosed from Wide-Field Optical Coherence Tomography In Singapore Adults With High Myopia.** *Acta Ophthalmol.* Epub 2020 Jun 29. <https://pubmed.ncbi.nlm.nih.gov/32602252/>
5. Mastropasqua R, Viggiano P, Borrelli E, Evangelista F, Libertini D, Di Antonio L, Toto L. **In Vivo Mapping of the Choriocapillaris in High myopia: a Widefield Swept Source Optical Coherence Tomography Angiography.** *Sci Rep.* 2019 Dec 12;9(1):18932. <https://pubmed.ncbi.nlm.nih.gov/31831754>
6. Schouten IM, Palkar AH, Bhende M. **Macular Vortex Vein with Choroidal Neovascularisation In Pathologic Myopia.** *Indian J Ophthalmol.* 2019 Oct;67(10):1717-1718. <https://pubmed.ncbi.nlm.nih.gov/31546529/>

Other Retina

1. Reich M, Boehringer D, Rothaus K, Cakir B, Bucher F, Daniel M, Lang SJ, Lagrèze WA, Agostini H, Lange C. **Swept-Source Optical Coherence Tomography Angiography Alleviates Shadowing Artifacts Caused By Subretinal Fluid.** *Int Ophthalmol.* 2020 Aug;40(8):2007-2016. <https://pubmed.ncbi.nlm.nih.gov/32333339/>
2. Terheyden JH, Wintergerst MWM, Pizarro C, Pfau M, Turski GN, Holz FG, Finger RP. **Retinal and Choroidal Capillary Perfusion Are Reduced in Hypertensive Crisis Irrespective of Retinopathy.** *Transl Vis Sci Technol.* 2020 Jul 29;9(8):42. <https://tvst.arvojournals.org/article.aspx?articleid=2770536>
3. Su L, Ji YS, Tong N, Sarraf D, He X, Sun X, Xu X, Sadda SR. **Quantitative Assessment of the Retinal Microvasculature And Choriocapillaris In Myopic Patients Using Swept-Source Optical Coherence Tomography Angiography.** *Graefes Arch Clin Exp Ophthalmol.* 2020 Jun;258(6):1173-1180. <https://pubmed.ncbi.nlm.nih.gov/32144487/>
4. Zheng F, Wong CW, Sabanayagam C, Cheung YB, Matsumura S, Chua J, Man REK, Ohno-Matsui K, Wong TY, Cheng CY, Tai ES, Lamoureux ELED, Schmetterer L, Kuo A, Hoang QV, Saw SM. **Prevalence, Risk Factors and Impact of Posterior Staphyloma Diagnosed From Wide-Field Optical Coherence Tomography In Singapore Adults with High Myopia.** *Acta Ophthalmol.* Epub 2020 Jun 29 <https://pubmed.ncbi.nlm.nih.gov/32602252/>
5. Tzaridis S, Hess K, Friedlander M, Holz FG. **Optical Coherence Tomography-Angiography for Monitoring Neovascularisations In Macular Telangiectasia Type 2.** *Br J Ophthalmol.* Epub 2020 Jun 8. <https://pubmed.ncbi.nlm.nih.gov/32513667/>
6. Sorour OA, Mehta N, Bauml CR, Ishibazawa A, Liu K, Konstantinou EK, Martin S, Braun P, Alibhai AY, Arya M, Witkin AJ, Duker JS, Waheed NK. **Morphological Changes In Intraretinal Microvascular Abnormalities After Anti-Vegf Therapy Visualized on Optical Coherence Tomography Angiography.** *Eye Vis (Lond).* 2020 Jun 1;7:29. <https://pubmed.ncbi.nlm.nih.gov/32514410/>
7. Nair A, Modi Y. **Disorganization of the Retinal Inner Layers as a Prognostic Biomarker.** *Retinal Physician.* 2020 May;17:16-19. <https://www.retinalphysician.com/issues/2020/may-2020/disorganization-of-the-retinal-inner-layers-as-a-p>
8. Siggel R, Spital C, Lentzsch A, Liakopoulos S. **Comparison of Automated versus Manually Modified OCT Angiography En Face Slabs for Detection of Choroidal Neovascularization.** *Ophthalmol Retina.* 2020 May;4(5):471-480. <https://pubmed.ncbi.nlm.nih.gov/32245653/>
9. Sakurada Y, Fragiotta S, Leong BCS, Parikh R, Hussnain SA, Freund KB. **Relationship Between Choroidal Vascular Hyperpermeability, Choriocapillaris Flow Density, and Choroidal Thickness In Eyes with Pachychoroid Pigment Epitheliopathy.** *Retina.* 2020 Apr;40(4):657-662. <https://pubmed.ncbi.nlm.nih.gov/31415450/>
10. D'Aloisio R, Viggiano P, Borrelli E, Parravano M, Agbèanda AG, Evangelista F, Ferro G, Toto L, Mastropasqua R. **Changes in Iris Perfusion Following Scleral Buckle Surgery for Rhegmatogenous Retinal Detachment: An Anterior Segment Optical Coherence Tomography Angiography (AS-OCTA) Study.** *J Clin Med.* 2020 Apr 24;9(4):1231. <https://pubmed.ncbi.nlm.nih.gov/32344742>
11. Al-Khersan H, Russell JF, Shi Y, Sridhar J, Gregori G, Flynn HW, Rosenfeld PJ. **Wide Field Swept Source OCT Angiography Of Multifocal Retinal And Choroidal Occlusions From Embolic Triamcinolone Acetonide.** *Am J Ophthalmol Case Rep.* 2020 Apr 14;18:100704. <https://pubmed.ncbi.nlm.nih.gov/32322753/>
12. Ogawa Y, Maruko I, Koizumi H, Iida T. **Quantification of Choroidal Vasculature By High-Quality Structure En Face Swept-Source Optical Coherence Tomography Images In Eyes With Central Serous Chorioretinopathy.** *Retina.* 2020 Mar;40(3):529-536. <https://pubmed.ncbi.nlm.nih.gov/30550530>
13. Barikian A, Davis J, Gregori G, Rosenfeld P. **Wide Field Swept Source OCT Angiography In Acute Syphilitic Placoid Chorioretinitis.** *Am J Ophthalmol. Case Rep.* 2020 Mar 27;18:100678. <https://pubmed.ncbi.nlm.nih.gov/32274447/>

14. Mastropasqua R, D'Aloisio R, De Nicola C, Ferro G, Senatore A, Libertini D, Di Marzio G, Di Nicola M, Di Martino G, Di Antonio L, Toto L. **Widefield Swept Source OCTA in Retinitis Pigmentosa.** *Diagnostics (Basel)*. 2020 Jan 19;10(1):50. <https://pubmed.ncbi.nlm.nih.gov/31963847>
15. Thulliez, M, Zhang, Q, Shi, Y, Zhou, H, Chu, Z, de Sisternes, L, Durbin, MK, Feuer, W, Gregori, G, Wang, RK, Rosenfeld, PJ. **Correlations between Choriocapillaris Flow Deficits around Geographic Atrophy and Enlargement Rates Based on Swept-Source OCT Imaging.** *Ophthalmol Retina*. 2019 [In press] [https://www.opthalmologyretina.org/article/S2468-6530\(18\)30617-1/fulltext](https://www.opthalmologyretina.org/article/S2468-6530(18)30617-1/fulltext)
16. Mastropasqua R, Viggiano P, Borrelli E, Evangelista F, Libertini D, Di Antonio L, Toto L. **In Vivo Mapping of the Choriocapillaris in High myopia: a Widefield Swept Source Optical Coherence Tomography Angiography.** *Sci Rep*. 2019 Dec 12;9(1):18932. <https://pubmed.ncbi.nlm.nih.gov/31831754>
17. Sacconi R, Tomasso L, Corbelli E, Carnevali A, Querques L, Casati S, Bandello F, Querques G. **Early Response To The Treatment Of Choroidal Neovascularization Complicating Central Serous Chorioretinopathy: A OCT-Angiography Study.** *Eye (Lond)*. 2019 Nov;33(11):1809-1817. <https://pubmed.ncbi.nlm.nih.gov/31267094>
18. Sahoo NK, Mishra SB, Iovino C, Singh SR, Munk MR, Berger L, Peiretti E, Chhablani J. **Optical Coherence Tomography Angiography Findings In Cystoid Macular Degeneration Associated with Central Serous Chorioretinopathy.** *Br J Ophthalmol*. 2019 Nov;103(11):1615-1618. <https://pubmed.ncbi.nlm.nih.gov/30602447/>
19. Reich M, Glatz A, Cakir B, Böhringer D, Lang S, Küchlin S, Joachimsen L, Lagreze W, Agostini HT, Lange C. **Characterisation Of Vascular Changes In Different Stages of Stargardt Disease Using Double Swept-Source Optical Coherence Tomography Angiography.** *BMJ Ophthalmology*. Epub 2019 Nov 2 <https://pubmed.ncbi.nlm.nih.gov/31799409/>
20. Karst SG, Beiglboeck H, Scharinger R, Meyer EL, Mitsch C, Scholda C, Schmidt-Erfurth UM. **Retinal and Choroidal Perfusion Status in the Area of Laser Scars Assessed with Swept-Source Optical Coherence Tomography Angiography.** *Invest Ophthalmol Vis Sci*. 2019 Nov 1;60(14):4865-4871. <https://pubmed.ncbi.nlm.nih.gov/31747687/>
21. Schouten IM, Palkar AH, Bhende M. **Macular Vortex Vein with Choroidal Neovascularisation In Pathologic Myopia.** *Indian J Ophthalmol*. 2019 Oct;67(10):1717-1718. <https://pubmed.ncbi.nlm.nih.gov/31546529/>
22. Matsumoto H, Kishi S, Mukai R, Akiyama H. **Remodeling of Macular Vortex Veins In Pachychoroid Neovascularopathy.** *Sci Rep*. 2019 Oct 11;9(1):14689. <https://pubmed.ncbi.nlm.nih.gov/31605004/>
23. Mastropasqua R, Senatore A, Di Antonio L, Di Nicola M, Marchioni M, Perna F, Amore F, Borrelli E, De Nicola C, Carpineto P, Toto L. **Correlation between Choriocapillaris Density and Retinal Sensitivity in Stargardt Disease.** *J Clin Med*. 2019 Sep 10;8(9):1432. <https://pubmed.ncbi.nlm.nih.gov/31510083/>
24. Spaide RF. **Diminutive Paracentral Acute Middle Maculopathy Lesion.** *Retin Cases Brief Rep*. Epub 2019 Jul 1. <https://pubmed.ncbi.nlm.nih.gov/31274851>
25. Fragiotta S, Leong BCS, Kaden TR, Bass SJ, Sherman J, Yannuzzi LA, Freund KB. **A Proposed Mechanism Influencing Structural Patterns In X-Linked Retinoschisis and Stellate Nonhereditary Idiopathic Foveomacular Retinoschisis.** *Eye (Lond)*. 2019 May;33(5):724-728. <https://pubmed.ncbi.nlm.nih.gov/30518975/>
26. Pellegrini M, Cozzi M, Staurengi G, Corvi F. **Comparison of Wide Field Optical Coherence Tomography Angiography with Extended Field Imaging and Fluorescein Angiography In Retinal Vascular Disorders.** *PLoS One*. 2019 Apr 9;14(4):e0214892. <https://pubmed.ncbi.nlm.nih.gov/30964919>
<https://journals.plos.org/plosone/article?id=10.1371/journal.pone.0214892>
27. Breazzano MP, Fernández-Avellaneda P, Freund KB. **Swept-Source Optical Coherence Tomography Angiography of Retinal Arterial Macroaneurysm with Overlying Hemorrhage.** *JAMA Ophthalmol*. Epub 2019 Apr 1 <https://pubmed.ncbi.nlm.nih.gov/30973588/>

28. Hayashi, K, Sato, T, Manabe, S-i, Hirata, A. **Sex-Related Differences in the Progression of Posterior Vitreous Detachment with Age.** *Ophthalmol Retina.* 2019 Mar;3(3):237-43
[https://www.opthalmologyretina.org/article/S2468-6530\(18\)30499-8/fulltext](https://www.opthalmologyretina.org/article/S2468-6530(18)30499-8/fulltext)
29. Leong, BC, Gal-Or, O, Freund, KB. **Optical Coherence Tomography Angiography of Retinal-Choroidal Anastomosis in Toxoplasmosis Chorioretinitis.** *JAMA ophthalmology.* 2019 Mar 1;137(3):e184091
<https://www.ncbi.nlm.nih.gov/pubmed/30869760>
30. Saraf SS, Tying AJ, Chen CL, Le TP, Kalina RE, Wang RK, Chao JR. **Familial Retinal Arteriolar Tortuosity and Quantification of Vascular Tortuosity Using Swept-Source Optical Coherence Tomography Angiography.** *Am J Ophthalmol Case Rep.* 2019 Mar 7;14:74-78. <https://pubmed.ncbi.nlm.nih.gov/30931409>
31. Casalino, G, Arrigo, A, Romano, F, Munk, MR, Bandello, F, Parodi, MB. **Acute Macular Neuroretinopathy: Pathogenetic Insights from Optical Coherence Tomography Angiography.** *Br J Ophthalmol.* 2019 Mar;109(3):410-14
<https://www.ncbi.nlm.nih.gov/pubmed/29844084>
32. Preziosa C, Milani P, Ciasca P, Bergamini F, Staurenghi G, Pellegrini M. **Optical Coherence Tomography Angiography Findings In a Case of Congenital Retinal Macrovascular with Anomalous Retinal Anastomosis Associated with Contralateral Myelinated Nerve Fibers and Retinal Vascular Abnormalities.** *Retin Cases Brief Rep.* Epub 2019 Feb 27.
<https://pubmed.ncbi.nlm.nih.gov/30830007>
33. Han IC, Whitmore SS, Critser BD, et al. **Wide-Field Swept-Source OCT and Angiography in X-Linked Retinoschisis.** *Ophthalmol Retina.* 2019 Feb;3(2): 178-85
[https://www.opthalmologyretina.org/article/S2468-6530\(18\)30424-X/fulltext](https://www.opthalmologyretina.org/article/S2468-6530(18)30424-X/fulltext)
34. Puyo L, Paques M, Fink M, Sahel J-A, Atlan M. **Choroidal Vasculature Imaging with Laser Doppler Holography.** *Biomed Opt Express.* 2019 Feb;10(2):995-1012
<https://www.ncbi.nlm.nih.gov/pmc/articles/PMC6377881/>
35. Motulsky E, Zheng F, Shi Y, Garcia JMB, Gregori G, Rosenfeld PJ. **Imaging of Epiretinal Membranes Using En Face Widefield Swept-Source Optical Coherence Tomography.** *Ophthalmic Surg Lasers Imaging Retina.* 2019 Feb 1;50(2):106-12 <https://www.ncbi.nlm.nih.gov/pubmed/30768218>
36. Rezkallah A, Kodjikian L, Abukhashabah A, Denis P, Mathis T. **Hypertensive Choroidopathy: Multimodal Imaging and the Contribution of Wide-Field Swept-Source OCT-Angiography.** *Am J Ophthalmol Case Rep.* 2019 Jan;9;13:131-35
<https://www.ncbi.nlm.nih.gov/pubmed/30705996>
37. Montorio D, Giuffrè C, Miserocchi E, Modorati G, Sacconi R, Mercuri S, Querques L, Querques G, Bandello F. **Swept-Source Optical Coherence Tomography Angiography in Serpiginous Choroiditis.** *Br J Ophthalmol.* 2018;102(7):991 <https://www.ncbi.nlm.nih.gov/pubmed/28982952>
38. Laueremann JL, Eter N, Alten F. **Optical Coherence Tomography Angiography Offers New Insights into Choriocapillaris Perfusion.** *Ophthalmologica.* 2018;239(2-3):74
<https://www.ncbi.nlm.nih.gov/pubmed/29353272>
39. Kashani AH, Green KM, Kwon J, Chu Z, Zhang Q, Wang RK, Garrity S, Sarraf D, Rebhun CB, Waheed NK, Schaal KB, Munk MR, Gattoussi S, Freund KB, Zheng F, Liu G, Rosenfeld PJ. **Suspended Scattering Particles in Motion: A Novel Feature of OCT Angiography in Exudative Maculopathies.** *Ophthalmol Retina.* 2018;2(7):694
<https://www.ncbi.nlm.nih.gov/pubmed/30221214>
40. Kashani AH, Green KM, Kwon J, Chu Z, Zhang Q, Wang RK, Garrity S, Sarraf D, Rebhun CB, Waheed NK, Schaal KB, Munk MR, Gattoussi S, Freund KB, Zheng F, Liu G, Rosenfeld PJ. **Suspended Scattering Particles in Motion: A Novel Feature of OCT Angiography in Exudative Maculopathies.** *Ophthalmol Retina.* 2018;2(7):694 <https://www.ncbi.nlm.nih.gov/pubmed/30221214>

41. Ogawa Y, Maruko I, Koizumi H, Iida T. **Quantification of Choroidal Vasculature by High-Quality Structure En Face Swept-Source Optical Coherence Tomography Images in Eyes with Central Serous Chorioretinopathy.** *Retina*. 2018 Dec [Epub ahead of print] <https://www.ncbi.nlm.nih.gov/pubmed/30550530>
42. Fragiotta S, Leong BCS, Kaden TR, Bass SJ, Sherman J, Yannuzzi LA, Freund KB. **A Proposed Mechanism Influencing Structural Patterns in X-Linked Retinoschisis and Stellate Nonhereditary Idiopathic Foveomacular Retinoschisis.** *Eye (Lond)*. 2018 Dec 5. doi: 10.1038/s41433-018-0296-8. [Epub ahead of print] <https://www.ncbi.nlm.nih.gov/pubmed/30518975>
43. Iesato Y, Tanaka M, Murata M, Kitahara J, Hirano T, Kurenuma T, Yoshida N, Murata T. **Complete Regression of Branching Vascular Network in Polypoidal Choroidal Vasculopathy by Ranibizumab and Photodynamic Therapy, Two Case Reports.** *BMC Ophthalmol*. 2018 Nov 3;18(1):284 <https://www.ncbi.nlm.nih.gov/pubmed/30390650>
44. Sakurada Y, Leong BCS, Parikh R, Fragiotta S, Freund KB. **Association between Choroidal Caverns and Choroidal Vascular Hyperpermeability in Eyes with Pachychoroid Diseases.** *Retina*. 2018 Oct;38(10):1977-83 <https://www.ncbi.nlm.nih.gov/pubmed/30198969>
45. Tran AQ, Yannuzzi NA, Motulsky EH, Zhou XY, Galor A, Dubovy SR, Rosenfeld PJ, Lam BL. **Swept-Source Optical Coherence Tomography Angiography of an Amalric Choroidal Infarction in a Rare Presentation of Giant Cell Arteritis with Bilateral Corneal Edema.** *Ophthalmic Surg Lasers Imaging Retina*. 2018 Oct 1;49(10):e157-60 <https://www.ncbi.nlm.nih.gov/pubmed/30395679>
46. Cornut T, Seguy C, Rougier MB, Delyfer MN, Morillon C, Korobelnik JF. **[Multimodal Imaging in Multiple Traumatic Choroidal Ruptures].** [Article in French]. *J Fr Ophtalmol*. 2018 Sep;41(7):676-78 <https://www.ncbi.nlm.nih.gov/pubmed/30166234>
47. Dolz-Marco R, Glover JP, Gal-Or O, Litts KM, Messinger JD, Zhang Y, Cozzi M, Pellegrini M, Freund KB, Staurenghi G, Curcio CA. **Choroidal and Sub-Retinal Pigment Epithelium Caverns: Multimodal Imaging and Correspondence with Friedman Lipid Globules.** *Ophthalmology*. 2018 Aug;125(8):1287-1301 <https://www.ncbi.nlm.nih.gov/pubmed/29625839>
48. Zucchiatti I, Sacconi R, Parravano MC, Costanzo E, Querques L, Montorio D, Bandello F, Querques G. **Eplerenone Versus Observation in the Treatment of Acute Central Serous Chorioretinopathy: A Retrospective Controlled Study.** *Ophthalmol Ther*. 2018 Jun;7(1):109 <https://www.ncbi.nlm.nih.gov/pubmed/29442283>
49. Paavo M, Zhao J, Kim HJ, Lee W, Zernant J, Cai C, Allikmets R, Tsang SH, Sparrow JR. **Mutations in Gpr143/Oa1 and Abca4 Inform Interpretations of Short-Wavelength and Near-Infrared Fundus Autofluorescence.** *Invest Ophthalmol Vis Sci*. 2018 May;59(6):2459-69 <https://www.ncbi.nlm.nih.gov/pubmed/29847651>
50. Rodriguez M, Gregori NZ, Roisman L, Lam BL, Rosenfeld PJ. **Swept-Source OCT Imaging of the Argus II Epiretinal Prosthesis.** *Ophthalmol Retina*. 2018 Apr;2(4):380-82 [https://www.opthalmologyretina.org/article/S2468-6530\(17\)30458-X/fulltext](https://www.opthalmologyretina.org/article/S2468-6530(17)30458-X/fulltext)
51. Carnevali A, Sacconi R, Corbelli E, Querques L, Bandello F, Querques G. **Choroidal Caverns: A Previously Unreported Optical Coherence Tomography Finding in Best Vitelliform Dystrophy.** *Ophthalmic Surg Lasers Imaging Retina*. 2018 Apr 1;49(4):284-87 <https://www.ncbi.nlm.nih.gov/pubmed/29664989>
52. Swaminathan SS, Shah P, Zheng F, Gregori G, Rosenfeld PJ. **Detection of Choriocapillaris Loss in Alport Syndrome with Swept-Source OCT Angiography.** *Ophthalmic Surg Lasers Imaging Retina*. 2018 Feb 1;49(2):138-41 <https://www.ncbi.nlm.nih.gov/pubmed/29443365>

53. Sacconi R, Freund KB, Yannuzzi LA, Dolz-Marco R, Souied E, Capuano V, Semoun O, Phasukkijwatana N, Sarraf D, Carnevali A, Querques L, Bandello F, Querques G. **The Expanded Spectrum of Perifoveal Exudative Vascular Anomalous Complex.** *Am J Ophthalmol.* 2017 Dec;184:137-46
<https://www.ncbi.nlm.nih.gov/pubmed/29079450>
54. Marchese A, Miserocchi E, Modorati G, Rabiolo A, Poggiali E, Lattanzio R, De Vitis L, Querques L, Querques G, Bandello F. **Widefield OCT Angiography of Idiopathic Retinal Vasculitis, Aneurysms, and Neuroretinitis.** *Ophthalmol Retina.* 2017 Nov-Dec;1(6):567-69
[https://www.opthalmologyretina.org/article/S2468-6530\(17\)30008-8/fulltext](https://www.opthalmologyretina.org/article/S2468-6530(17)30008-8/fulltext)
55. Stein G, Zheng F, Tran AQ, Dias JR, Motulsky EH, Gregori G, Rosenfeld PJ. **Swept-Source OCT Angiography of Polypoidal Choroidal Vasculopathy Using Boundary Layer Specific Segmentation.** *Invest Ophthalmol Vis Sci.* 2017 Jun;58(8):1698 <https://iovs.arvojournals.org/article.aspx?articleid=2637816&resultClick=1>
56. Schaal KB, Legarreta AD, Feuer WJ, Gregori G, Cheng Q, Legarreta JE, Durbin MK, Stetson PF, Kubach S, Rosenfeld PJ. **Comparison between Widefield En Face Swept-Source OCT and Conventional Multimodal Imaging for the Detection of Reticular Pseudodrusen.** *Ophthalmology.* 2017 Feb;124(2):205-14
<https://www.ncbi.nlm.nih.gov/pubmed/27856030>
57. Yannuzzi NA, Swaminathan SS, Zheng F, Miller A, Gregori G, Davis JL, Rosenfeld PJ. **Swept-Source OCT Angiography Shows Sparing of the Choriocapillaris in Multiple Evanescent White Dot Syndrome.** *Ophthalmic Surg Lasers Imaging Retina.* 2017 Jan 1;48(1):69-74 <https://www.ncbi.nlm.nih.gov/pubmed/28060397>
58. Robbins G, Roisman L, Zhang Q, Wang RK, Gregori G, Chen CL, Durbin M, Stetson PF, Legarreta AD, Miller A, Rosenfeld PJ. **OCT Angiography (OCTA) of Neovascularization in Macular Telangiectasia Type 2.** *Invest Ophthalmol Vis Sci.* 2016 Sep;57(12):5502 <https://iovs.arvojournals.org/article.aspx?articleid=2563579&resultClick=1>
59. Jung JJ, Chen MH, Frambach CR, Rofagha S, Lee SS. **Spectral Domain Versus Swept-Source Optical Coherence Tomography Angiography of the Retinal Capillary Plexuses in Sickle Cell Maculopathy.** *Retin Cases Brief Rep.* 2016 Spring;12(2):87-92 <https://www.ncbi.nlm.nih.gov/pubmed/27749746>
<https://insights.ovid.com/pubmed?pmid=27749746>
60. Zhang Q, Wang RK, Chen CL, Legarreta AD, Durbin MK, An L, Sharma U, Stetson PF, Legarreta JE, Roisman L, Gregori G, Rosenfeld PJ. **Swept-Source Optical Coherence Tomography Angiography of Neovascular Macular Telangiectasia Type 2.** *Retina.* 2015 Nov;35(11):2285-99
<https://www.ncbi.nlm.nih.gov/pubmed/26457402>
<https://www.ncbi.nlm.nih.gov/pmc/articles/PMC4623930/pdf/nihms-721576.pdf>
61. Thorell MR, Zhang Q, Huang Y, An L, Durbin MK, Laron M, Sharma U, Stetson PF, Gregori G, Wang RK, Rosenfeld PJ. **Swept-Source OCT Angiography of Macular Telangiectasia Type 2.** *Ophthalmic Surg Lasers Imaging Retina.* 2014;45(5):369-380 <https://www.ncbi.nlm.nih.gov/pubmed/25291783>
<https://www.healio.com/ophthalmology/journals/osli/2014-9-45-5/%7B849feaaa-8a02-4232-92ec-8b4fd894db7d%7D/swept-source-oct-angiography-of-macular-telangiectasia-type-2>

Quantification

1. Chu Z, Weinstein JE, Wang RK, Pepple KL. **Quantitative Analysis of the Choriocapillaris in Uveitis Using en face Swept Source Optical Coherence Tomography Angiography.** *Am J Ophthalmol.* 2020 Oct;218:17-27. <https://pubmed.ncbi.nlm.nih.gov/32413411>
2. Terheyden JH, Wintergerst MWM, Pizarro C, Pfau M, Turski GN, Holz FG, Finger RP. **Retinal and Choroidal Capillary Perfusion Are Reduced in Hypertensive Crisis Irrespective of Retinopathy.** *Transl Vis Sci Technol.* 2020 Jul 29;9(8):42. <https://tvst.arvojournals.org/article.aspx?articleid=2770536>
<https://pubmed.ncbi.nlm.nih.gov/32855888>
3. Lo J, Heisler M, Vanzan V, Karst S, Matovinović IZ, Lončarić S, Navajas EV, Beg MF, Šarunić MV. **Microvasculature Segmentation and Intercapillary Area Quantification of the Deep Vascular Complex Using Transfer Learning.** *Transl Vis Sci Technol.* 2020 Jul 10;9(2):38. <https://pubmed.ncbi.nlm.nih.gov/32855842/>
4. Lin E, Ke M, Tan B, Yao X, Wong D, Ong L, Schmetterer L, Chua J. **Are Choriocapillaris Flow Void Features Robust To Diurnal Variations? A Swept-Source Optical Coherence Tomography Angiography (OCTA) Study.** *Sci. Rep.* 2020 Jul 9;10(1):11249. <https://pubmed.ncbi.nlm.nih.gov/32647298/>
5. Su L, Ji YS, Tong N, Sarraf D, He X, Sun X, Xu X, Sadda SR. **Quantitative Assessment of the Retinal Microvasculature And Choriocapillaris In Myopic Patients Using Swept-Source Optical Coherence Tomography Angiography.** *Graefes Arch Clin Exp Ophthalmol.* 2020 Jun;258(6):1173-1180. <https://pubmed.ncbi.nlm.nih.gov/32144487/>
6. Ji YS, Alagorie AR, Byon I, Sadda SR. **Impact of Scan Tilt on Quantitative Assessments Using Optical Coherence Tomography Angiography.** *Transl Vis Sci Technol.* 2020 Jun 30;9(7):46. <https://pubmed.ncbi.nlm.nih.gov/32832251/>
7. Toto L, D'Aloisio R, Chiarelli AM, Di Antonio L, Evangelista F, D'Onofrio G, Merla A, Parravano M, Di Marzio G, Mastropasqua R. **A Custom-Made Semiautomatic Analysis of Retinal Nonperfusion Areas After Dexamethasone for Diabetic Macular Edema.** *Transl Vis Sci Technol.* 2020 Jun 11;9(7):13. <https://tvst.arvojournals.org/article.aspx?articleid=2766327>
<https://pubmed.ncbi.nlm.nih.gov/32832220>
8. Tzaridis S, Hess K, Friedlander M, Holz FG. **Optical Coherence Tomography-Angiography for Monitoring Neovascularisations In Macular Telangiectasia Type 2.** *Br J Ophthalmol.* Epub 2020 Jun 8
<https://pubmed.ncbi.nlm.nih.gov/32513667/>
9. Heisler M, Karst S, Lo J, Mammo Z, Yu T, Warner S, Maberley D, Beg MF, Navajas EV, Sarunic MV. **Ensemble Deep Learning for Diabetic Retinopathy Detection Using Optical Coherence Tomography Angiography.** *Transl Vis Sci Technol.* 2020 Apr 13;9(2):20. <https://pubmed.ncbi.nlm.nih.gov/32818081/>
10. Ogawa Y, Maruko I, Koizumi H, Iida T. **Quantification of Choroidal Vasculature By High-Quality Structure En Face Swept-Source Optical Coherence Tomography Images In Eyes with Central Serous Chorioretinopathy.** *Retina.* 2020 Mar;40(3):529-536. <https://pubmed.ncbi.nlm.nih.gov/30550530>
11. Dai Y, Zhou H, Chu Z, Zhang Q, Chao JR, Rezaei KA, Wang RK. **Microvascular Changes in the Choriocapillaris of Diabetic Patients Without Retinopathy Investigated by Swept-Source OCT Angiography.** *Invest Ophthalmol Vis Sci.* 2020 Mar 9;61(3):50. <https://pubmed.ncbi.nlm.nih.gov/32232345/>
12. Aicher NT, Nagahori K, Inoue M, Itoh Y, Hirakata A. **Vascular Density of Anterior Segment of Eye Determined By Optical Coherence Tomography Angiography and Slit-Lamp Photography.** *Ophthalmic Res.* Epub 2020 Mar 5. <https://pubmed.ncbi.nlm.nih.gov/32135544/>

13. Ohayon A, Sacconi R, Semoun O, Corbelli E, Souied EH, Querques G. **Choroidal Neovascular Area and Vessel Density Comparison Between Two Swept-Source Optical Coherence Tomography Angiography Devices.** *Retina.* 2020 Mar;40(3):521-528. <https://pubmed.ncbi.nlm.nih.gov/30589664/>
14. Alibhai AY, De Pretto LR, Moulton EM, Or C, Arya M, McGowan M, Carrasco-Zevallos O, Lee B, Chen S, Baurnal CR, Witkin AJ, Reichel E, de Freitas AZ, Duker JS, Fujimoto JG, Waheed NK. **Quantification of Retinal Capillary Nonperfusion in Diabetics Using Wide-Field Optical Coherence Tomography Angiography.** *Retina.* 2020 Mar;40(3):412-420. <https://pubmed.ncbi.nlm.nih.gov/30576300/>
15. Lee MW, Park HJ, Shin YI, Lee WH, Lim HB, Kim JY. **Comparison of Choroidal Thickness Measurements Using Swept Source and Spectral Domain Optical Coherence Tomography In Pachychoroid Diseases.** *PLoS One.* 2020 Feb 26;15(2):e0229134. <https://pubmed.ncbi.nlm.nih.gov/32101541>
16. Tan B, Chua J, Lin E, Cheng J, Gan A, Yao X, Wong DWK, Sabanayagam C, Wong D, Chan CM, Wong TY, Schmetterer L, Tan GS. **Quantitative Microvascular Analysis With Wide-Field Optical Coherence Tomography Angiography in Eyes With Diabetic Retinopathy.** *JAMA Netw Open.* 2020 Jan 3;3(1):e1919469. <https://pubmed.ncbi.nlm.nih.gov/31951275/>
17. Chu Z, Gregori G, Rosenfeld PJ, Wang RK. **Quantification of Choriocapillaris with Optical Coherence Tomography Angiography: A Comparison Study.** *Am J Ophthalmol.* 2019 Dec;208:111-123. <https://pubmed.ncbi.nlm.nih.gov/31323202/>
18. Sacconi R, Borrelli E, Corbelli E, Capone L, Rabiolo A, Carnevali A, Casaluci M, Gelormini F, Querques L, Bandello F, Querques G. **Quantitative Changes In the Ageing Choriocapillaris as Measured By Swept Source Optical Coherence Tomography Angiography.** *Br J Ophthalmol.* 2019 Sep;103(9):1320-1326. <https://pubmed.ncbi.nlm.nih.gov/30361273/>
19. Mehta N, Liu K, Alibhai AY, Gendelman I, Braun PX, Ishibazawa A, Sorour O, Duker JS, Waheed NK. **Impact of Binarization Thresholding and Brightness/Contrast Adjustment Methodology on Optical Coherence Tomography Angiography Image Quantification.** *Am Journal.* 2019 Sep;205:54-65. <https://pubmed.ncbi.nlm.nih.gov/30885708>
20. Rinella NT, Zhou H, Zhang Q, Keiner C, Oldenburg CE, Duncan JL, Wang RK, Schwartz DM. **Quantifying Choriocapillaris Flow Voids in Patients With Geographic Atrophy Using Swept-Source OCT Angiography.** *Ophthalmic Surg Lasers Imaging Retina.* 2019 Sep 1;50(9):e229-e235. <https://pubmed.ncbi.nlm.nih.gov/31589763/>
21. Tzaridis S, Wintergerst MWM, Mai C, Heeren TFC, Holz FG, Issa PC, Herrmann P. **Quantification of Retinal and Choriocapillaris Perfusion in Different Stages of Macular Telangiectasia Type 2.** *Invest Ophthalmol Vis Sci.* 2019 Aug 1;60(10):3556-3562. <https://pubmed.ncbi.nlm.nih.gov/31415079>
22. Tepelus TC, Song S, Borrelli E, Nittala MG, Baghdasaryan E, Sadda SR, Chopra V. **Quantitative Analysis of Retinal and Choroidal Vascular Parameters in Patients With Low Tension Glaucoma.** *J Glaucoma.* 2019 Jun;28(6):557-562. <https://pubmed.ncbi.nlm.nih.gov/30889061>
23. Saraf SS, Tying AJ, Chen CL, Le TP, Kalina RE, Wang RK, Chao JR. **Familial Retinal Arteriolar Tortuosity And Quantification Of Vascular Tortuosity Using Swept-Source Optical Coherence Tomography Angiography.** *Am J Ophthalmol Case Rep.* Epub 2019 Mar 7. <https://pubmed.ncbi.nlm.nih.gov/30931409>
24. Chu Z, Zhang Q, Zhou H, Shi Y, Zheng F, Gregori G, Rosenfeld PJ, Wang RK. **Quantifying Choriocapillaris Flow Deficits Using Global and Localized Thresholding Methods: A Correlation Study.** *Quant Imaging Med Surg.* 2018 Dec;8(11):1102 <https://www.ncbi.nlm.nih.gov/pubmed/30701164>
25. Tan B, Chua J, Barathi VA, Baskaran M, Chan A, Lin E, Ang M, Klose G, Schmetterer L. **Quantitative Analysis of Choriocapillaris in Non-Human Primates Using Swept-Source Optical Coherence Tomography Angiography (SS-OCTA).** *Biomed Opt Express.* 2018 Dec 21;10(1):356-71 <https://www.ncbi.nlm.nih.gov/pubmed/30775105>

26. Chu Z, Zhou H, Cheng Y, Zhang Q, Wang RK. **Improving Visualization and Quantitative Assessment of Choriocapillaris with Swept-Source OCTA through Registration and Averaging Applicable to Clinical Systems.** *Sci Rep.* 2018 Nov 14;8(1) <https://www.nature.com/articles/s41598-018-34826-5>
27. Rabiolo A, Gelormini F, Sacconi R, Cicinelli MV, Triolo G, Bettin P, Nouri-Mahdavi K, Bandello F, Querques G. **Comparison of Methods to Quantify Macular and Peripapillary Vessel Density in Optical Coherence Tomography Angiography.** *PLoS One.* 2018 Oct 18;13(10):e0205773 <https://www.ncbi.nlm.nih.gov/pubmed/30335815>
28. Yu S, Frueh BE, Steinmair D, Ebnetter A, Wolf S, Zinkernagel MS, Munk MR. **Cataract Significantly Influences Quantitative Measurements on Swept-Source Optical Coherence Tomography Angiography Imaging.** *PLoS One.* 2018 Oct 2;13(10):e0204501 <https://www.ncbi.nlm.nih.gov/pubmed/30278057>
29. Dolz-Marco R, Glover JP, Gal-Or O, Litts KM, Messinger JD, Zhang Y, Cozzi M, Pellegrini M, Freund KB, Staurengi G, Curcio CA. **Choroidal and Sub-Retinal Pigment Epithelium Caverns: Multimodal Imaging and Correspondence with Friedman Lipid Globules.** *Ophthalmology.* 2018 Aug;125(8):1287-1301 <https://www.ncbi.nlm.nih.gov/pubmed/29625839>
30. Rabiolo A, Gelormini F, Marchese A, Cicinelli MV, Triolo G, Sacconi R, Querques L, Bandello F, Querques G. **Macular Perfusion Parameters in Different Angiocube Sizes: Does the Size Matter in Quantitative Optical Coherence Tomography Angiography?** *Invest Ophthalmol Vis Sci.* 2018 Jan 1;59(1):231-37 <https://www.ncbi.nlm.nih.gov/pubmed/29340651>
31. Zhang Q, Zheng F, Motulsky EH, Gregori G, Chu Z, Chen CL, Li C, de Sisternes L, Durbin M, Rosenfeld PJ, Wang RK. **A Novel Strategy for Quantifying Choriocapillaris Flow Voids Using Swept-Source OCT Angiography.** *Invest Ophthalmol Vis Sci.* 2018 Jan 1;59(1):203-11 <https://www.ncbi.nlm.nih.gov/pubmed/29340648>
32. Zhang Q, Chen CL, Chu Z, Zheng F, Miller A, Roisman L, Rafael de Oliveira Dias J, Yehoshua Z, Schaal KB, Feuer W, Gregori G, Kubach S, An L, Stetson PF, Durbin MK, Rosenfeld PJ, Wang RK. **Automated Quantitation of Choroidal Neovascularization: A Comparison Study between Spectral-Domain and Swept-Source OCT Angiograms.** *Invest Ophthalmol Vis Sci.* 2017 Mar 1;58(3):1506-13 <https://www.ncbi.nlm.nih.gov/pubmed/28273317>
33. Chu Z, Lin J, Gao C, Xin C, Zhang Q, Chen CL, Roisman L, Gregori G, Rosenfeld PJ, Wang RK. **Quantitative Assessment of the Retinal Microvasculature Using Optical Coherence Tomography Angiography.** *J Biomed Opt.* 2016 Jun 1;21(6):66008 <https://www.ncbi.nlm.nih.gov/pubmed/27286188>

Swept-Source OCT & OCTA Technology

1. Ledesma-Gil G, Fernandez-Avellaneda P, Spaide RF. **Swept-Source Optical Coherence Tomography Angiography Image Compensation of the Choriocapillaris Induces Artifacts.** *Retina.* 2020 Oct;40(10):1865-1872. <https://pubmed.ncbi.nlm.nih.gov/32453067>
2. Reich M, Boehringer D, Rothaus K, Cakir B, Bucher F, Daniel M, Lang SJ, Lagrèze WA, Agostini H, Lange C. **Swept-source optical coherence tomography angiography alleviates shadowing artifacts caused by subretinal fluid.** *Int Ophthalmol.* 2020 Aug;40(8):2007-2016. <https://pubmed.ncbi.nlm.nih.gov/32333339/>
3. Corvi F, Sadda SR, Staurengi G, Pellegrini M. **Thresholding Strategies To Measure Vessel Density By Optical Coherence Tomography Angiography.** *Can j Ophthalmol.* 2020 Aug;55(4):317-322. <https://pubmed.ncbi.nlm.nih.gov/32439196/>
4. Beck M, Joshi DS, Berger L, Klose G, De Zanet S, Mosinska A, Apostolopoulos S, Ebnetter A, Zinkernagel MS, Wolf S, Munk MR. **Comparison of Drusen Volume Assessed by Two Different OCT Devices.** *J Clin Med.* 2020 Aug 17;9(8):2657. <https://www.mdpi.com/2077-0383/9/8/2657/htm>
<https://pubmed.ncbi.nlm.nih.gov/32824455>
5. Ito H, Ito Y, Kataoka K, Ueno S, Takeuchi J, Nakano Y, Fujita A, Horiguchi E, Kaneko H, Iwase T, Terasaki H. **Association Between Retinal Layer Thickness and Perfusion Status in Extramacular Areas in Diabetic Retinopathy.** *Am J Ophthalmol.* 2020 Jul;215:25-36. <https://pubmed.ncbi.nlm.nih.gov/32224103>
6. Tian M, Wolf S, Munk MR, Schaal KB. **Evaluation of Different Swept-source Optical Coherence Tomography Angiography (SS-OCTA) Slabs For the Detection of Features Of Diabetic Retinopathy.** *Acta Ophthalmol.* 2020 Jun;98(4):e416-e420. <https://pubmed.ncbi.nlm.nih.gov/31663681>
7. Ji YS, Alagorie AR, Byon I, Sadda SR. **Impact of Scan Tilt on Quantitative Assessments Using Optical Coherence Tomography Angiography.** *Transl Vis Sci Technol.* 2020 Jun 30;9(7):46. <https://pubmed.ncbi.nlm.nih.gov/32832251/>
8. Chu Z, Cheng Y, Zhang Q, Zhou H, Dai Y, Shi Y, Gregori G, Rosenfeld PJ, Wang RK. **Quantification of Choriocapillaris with Phansalkar Local Thresholding: Pitfalls to Avoid.** *Am J Ophthalmol.* 2020 May;213:161-176. <https://pubmed.ncbi.nlm.nih.gov/32059979/>
9. Siggel R, Spital C, Lentzsch A, Liakopoulos S. **Comparison of Automated versus Manually Modified OCT Angiography En Face Slabs for Detection of Choroidal Neovascularization.** *Ophthalmol Retina.* 2020 May;4(5):471-480. <https://pubmed.ncbi.nlm.nih.gov/32245653/>
10. Liu K, Mehta N, Alibhai AY, Arya M, Sorour O, Ishibazawa A, Byon I, Baomal CR, Witkin AJ, Duker JS, Sadda SR, Waheed NK. **Effects Of Enhanced Depth Imaging and En Face Averaging on Optical Coherence Tomography Angiography Image Quantification.** *Graefes Arch Clin Exp Ophthalmol.* 2020 May;258(5):979-986. <https://pubmed.ncbi.nlm.nih.gov/32020294/>
11. Yao X, Ke M, Ho Y, Lin E, Wong DWK, Tan B, Schmetterer L, Chua J. **Comparison of Retinal Vessel Diameter Measurements From Swept-Source OCT Angiography and Adaptive Optics Ophthalmoscope.** *Br J Ophthalmol.* Epub 2020 May 27. <https://pubmed.ncbi.nlm.nih.gov/32461263>
12. Byon I, Alagorie AR, Ji Y, Su L, Sadda SR. **Optimizing the Repeatability of Choriocapillaris Flow Deficit Measurement from Optical Coherence Tomography Angiography.** *Am J Ophthalmol.* 2020 May 23;219:21-32. <https://pubmed.ncbi.nlm.nih.gov/32454035>
13. Heisler M, Karst S, Lo J, Mammo Z, Yu T, Warner S, Maberley D, Beg MF, Navajas EV, Sarunic MV. **Ensemble Deep Learning for Diabetic Retinopathy Detection Using Optical Coherence Tomography Angiography.** *Transl Vis Sci Technol.* 2020 Apr 13;9(2):20. <https://pubmed.ncbi.nlm.nih.gov/32818081/>

14. Fragiotta S, Fernández-Avellaneda P, Breazzano MP, Yannuzzi LA, Curcio CA, Freund KB. **Linear and Planar Reflection Artifacts On Swept-Source and Spectral-Domain Optical Coherence Tomography Due To Hyperreflective Crystalline Deposits.** *Graefes Arch Clin Exp Ophthalmol.* 2020 Mar;258(3):491-501. <https://pubmed.ncbi.nlm.nih.gov/31879821/>
15. Terheyden JH, Wintergerst MWM, Falahat P, Berger M, Holz FG, Finger RP. **Automated Thresholding Algorithms Outperform Manual Thresholding In Macular Optical Coherence Tomography Angiography Image Analysis.** *PLoS One.* 2020 Mar 20;15(3):e0230260. <https://pubmed.ncbi.nlm.nih.gov/32196538>
16. Zhou H, Dai Y, Gregori G, Rosenfeld PR, Duncan JL, Schwartz DM, Wang RK. **Automated Morphometric Measurement of the Retinal Pigment Epithelium Complex And Choriocapillaris Using Swept Source OCT.** *Biomed Opt Express.* 2020 Mar 6;11(4):1834-1850. <https://pubmed.ncbi.nlm.nih.gov/32341851/>
17. Barikian AW, Flynn Jr. HW, Rosenfeld PJ. **The Clinical Utility of Swept-Source OCT Angiography for the Retinal Physician Image Flow And Structure From the Vitreous Through the Choroid.** *Retinal Physician.* 2020 JanFeb;17:18-22. <https://www.retinalphysician.com/issues/2020/jan-feb-2020/the-clinical-utility-of-swept-source-oct-angiograp>
18. Borrelli E, Toto L, Viggiano P, Evangelista F, Palmieri M, Mastropasqua R. **Widefield Topographical Analysis of the Retinal Perfusion and Neuroretinal Thickness In Healthy Eyes: A Pilot Study.** *Eye (Lond).* Epub 2020 Feb 13. <https://pubmed.ncbi.nlm.nih.gov/32055020/>
19. Tsuji S, Sekiryu T, Sugano Y, Ojima A, Kasai A, Okamoto M, Eifuku S. **Semantic Segmentation of the Choroid in Swept Source Optical Coherence Tomography Images for Volumetrics.** *Sci Rep.* 2020 Jan 23;10(1):1088. <https://pubmed.ncbi.nlm.nih.gov/31974487/>
20. Hong J, Tan B, Quang ND, Gupta P, Lin E, Wong D, Ang M, Lamoureux E, Schmetterer L, Chua J. **Intra-Session Repeatability of Quantitative Metrics Using Widefield Optical Coherence Tomography Angiography (OCTA) In Elderly Subjects.** *Acta Ophthalmol.* Epub 2019 Dec 12. <https://pubmed.ncbi.nlm.nih.gov/31833241/>
21. Borrelli E, Sacconi R, Klose G, de Sisternes L, Bandello F, Querques G. **Rotational Three-dimensional OCTA: a Notable New Imaging Tool to Characterize Type 3 Macular Neovascularization.** *Sci Rep.* 2019 Nov 19;9(1):17053. <https://pubmed.ncbi.nlm.nih.gov/31745216>
22. Borrelli E, Sacconi R, Brambati M, Bandello F, Querques G. **In Vivo Rotational Three-Dimensional OCTA Analysis of Microaneurysms In The Human Diabetic Retina.** *Sci Rep.* 2019 Nov 14;9(1):16789. <https://pubmed.ncbi.nlm.nih.gov/31728070>
23. Borrelli E, Viggiano P, Evangelista F, Toto L, Mastropasqua R. **Eyelashes Artifact in Ultra-Widefield Optical Coherence Tomography Angiography.** *Ophthalmic Surg Lasers Imaging Retina.* 2019 Nov 1;50(11):740-743. <https://pubmed.ncbi.nlm.nih.gov/31755975/>
24. Mehta N, Liu K, Alibhai AY, Gendelman I, Braun PX, Ishibazawa A, Sorour O, Duker JS, Waheed NK. **Impact of Binarization Thresholding and Brightness/Contrast Adjustment Methodology on Optical Coherence Tomography Angiography Image Quantification.** *Am Journal.* 2019 Sep;205:54-65. <https://pubmed.ncbi.nlm.nih.gov/30885708>
25. Borrelli E, Sadda SR, Uji A, Querques G. **Pearls and Pitfalls of Optical Coherence Tomography Angiography Imaging: A Review. Pearls and Pitfalls of Optical Coherence Tomography Angiography Imaging: A Review.** *Ophthalmol Ther.* 2019 Jun;8(2):215-226. <https://pubmed.ncbi.nlm.nih.gov/30868418/>
<https://www.ncbi.nlm.nih.gov/pmc/articles/PMC6513942/>
26. Ishibazawa A, Mehta N, Sorour O, Braun P, Martin S, Alibhai AY, Saifuddin A, Arya M, Baumal CR, Duker JS, Waheed NK. **Accuracy and Reliability in Differentiating Retinal Arteries and Veins Using Widefield En Face OCT Angiography.** *Transl Vis Sci Technol.* 2019 Jun 28;8(3):60. <https://pubmed.ncbi.nlm.nih.gov/31316862>

27. De Pretto LR, Moulton EM, Alibhai AY, Carrasco-Zevallos OM, Chen S, Lee B, Witkin AJ, Bauman CR, Reichel E, de Freitas AZ, Duker JS, Waheed NK, Fujimoto JG. **Controlling for Artifacts in Widefield Optical Coherence Tomography Angiography Measurements of Non-Perfusion Area.** *Sci Rep.* 2019 Jun 24;9(1):9096. <https://pubmed.ncbi.nlm.nih.gov/31235795/>
28. Eastline M, Munk MR, Wolf S, Schaal KB, Ebner A, Tian M, Giannakaki-Zimmermann H, Zinkernagel MS. **Repeatability of Wide-field Optical Coherence Tomography Angiography in Normal Retina.** *Transl Vis Sci Technol.* 2019 May 2;8(3):6. <https://pubmed.ncbi.nlm.nih.gov/31106033>
29. Parravano M, Borrelli E, Sacconi R, Costanzo E, Marchese A, Manca D, Varano M, Bandello F, Querques G. **A Comparison Among Different Automatically Segmented Slabs to Assess Neovascular AMD using Swept Source OCT Angiography.** *Transl Vis Sci Technol.* 2019 Mar 27;8(2):8. <https://pubmed.ncbi.nlm.nih.gov/30941265>
30. Saraf SS, Tying AJ, Chen CL, Le TP, Kalina RE, Wang RK, Chao JR. **Familial Retinal Arteriolar Tortuosity and Quantification of Vascular Tortuosity Using Swept-Source Optical Coherence Tomography Angiography.** *Am J Ophthalmol Case Rep.* 2019 Mar 7;14:74-78. <https://pubmed.ncbi.nlm.nih.gov/30931409>
31. Lee WD, Devarajan K, Chua J, Schmetterer L, Mehta JS, Ang M. **Optical Coherence Tomography Angiography for the Anterior Segment.** *Eye Vis (Lond).* 2019 Feb 1;6:4. <https://pubmed.ncbi.nlm.nih.gov/30775387/>
32. Sacconi R, Borrelli E, Corbelli E, Capone L, Rabiolo A, Carnevali A, Casaluci M, Gelormini F, Querques L, Bandello F, Querques G. **Quantitative Changes in the Ageing Choriocapillaris as Measured by Swept-Source Optical Coherence Tomography Angiography.** *Br J Ophthalmol.* 2018 Oct 25. doi: 10.1136/bjophthalmol-2018-313004 [Epub ahead of print] <https://www.ncbi.nlm.nih.gov/pubmed/30361273>
33. Sacconi R, De Vitis LA, Carnevali A, Albertini G, Cavalleri M, Querques L, Querques G, Bandello F, Shields CL, DiNicola M, Shields JA. **Diagnostic and Therapeutic Challenges.** *Retina.* 2018 May;38(5):1058-61 <https://www.ncbi.nlm.nih.gov/pubmed/28654456>
34. Balaratnasingam C, An D, Sakurada Y, Lee CS, Lee AY, McAllister IL, Freund KB, Sarunic M, Yu DY. **Comparisons between Histology and Optical Coherence Tomography Angiography of the Periarterial Capillary-Free Zone.** *Am J Ophthalmol.* 2018 May;189:55-64 <https://www.ncbi.nlm.nih.gov/pubmed/29470970>
35. Li Y, Xia X, Paulus Y. **Advances in Retinal Optical Imaging.** *Photonics.* 2018 Apr 27;5(2) <https://www.mdpi.com/2304-6732/5/2/9>
36. Tan B, Wong A, Bizheva K. **Enhancement of Morphological and Vascular Features in OCT Images Using a Modified Bayesian Residual Transform.** *Biomed Opt Express.* 2018 Apr 27;9(5):2394-2406 <https://www.ncbi.nlm.nih.gov/pubmed/29760996>
37. Jung JJ, Chen MH, Frambach CR, Rofagha S, Lee SS. **Spectral Domain Versus Swept-Source Optical Coherence Tomography Angiography of the Retinal Capillary Plexuses in Sickle Cell Maculopathy.** *Retin Cases Brief Rep.* 2018 Spring;12(2):87-92 <https://www.ncbi.nlm.nih.gov/pubmed/27749746>
38. Lang GE, Enders C, Loidl M, Lang GK, Werner JU. **[Accurate OCT-Angiography Interpretation – Detection and Exclusion of Artifacts].** [Article in German] *Klin Monbl Augenheilkd.* 2017 Sep;234(9):1109-118 <https://www.ncbi.nlm.nih.gov/pubmed/28628928>
39. Kashani AH, Chen CL, Gahm JK, Zheng F, Richter GM, Rosenfeld PJ, Shi Y, Wang RK. **Optical Coherence Tomography Angiography: A Comprehensive Review of Current Methods and Clinical Applications.** *Prog Retin Eye Res.* 2017 Sep;60:66-100 <https://www.ncbi.nlm.nih.gov/pubmed/28760677>
40. Tumlinson AR, Rahman F, Magazzeni S, Rochendorfer P, Shemonski N. **The Advanced Retina Imaging Network Hub Online Tools for OCT Innovation.** *Invest Ophthalmol Vis Sci.* 2017 Jun;58(8):1864 <https://iovs.arvojournals.org/article.aspx?articleid=2639646&resultClick=1>

41. Bagherinia H, Knighton RW, De Sisternes L, Chen MH, Durbin M. **A Fast Method to Reduce Decorrelation Tail Artifacts in OCT Angiography.** *Invest Ophthalmol Vis Sci.* 2017 Jun;58(8):643
<https://iovs.arvojournals.org/article.aspx?articleid=2637956&resultClick=1>
42. Su GL, Baughman DM, Zhang Q, Rezaei K, Lee AY, Lee CS. **Comparison of Retina Specialist Preferences Regarding Spectral-Domain and Swept-Source Optical Coherence Tomography Angiography.** *Clin Ophthalmol.* May 15;11:889-95 <https://www.ncbi.nlm.nih.gov/pubmed/28553068>
<https://www.dovepress.com/getfile.php?fileID=36484>
43. Fathipour V, Schmoll T, Bonakdar A, Wheaton S, Mohseni H. **Demonstration of Shot-Noise-Limited Swept-Source OCT without Balanced Detection.** *Sci Rep.* 2017 Apr 26;7(1):1183 <https://www.ncbi.nlm.nih.gov/pubmed/28446793>
https://www.ncbi.nlm.nih.gov/pmc/articles/PMC5430670/pdf/41598_2017_Article_1339.pdf
44. Cole ED, Duker JS. **OCT Technology: Will We Be “Swept” Away?** *Review of Ophthalmology wesbite.* April 7, 2017
<https://www.reviewofophthalmology.com/article/OCT-technology-will-we-be-swept-away>
45. Zhang Q, Chen C-L, Chu Z, Wang RK. **Wide Field OCT Angiography by Using Swept-Source OCT in Living Human Eye.** *Ophthalmic Technologies XXVII.* 2017 Feb 8;10045:100450V doi: 10.1117/12.2251029
https://spie.org/Publications/Proceedings/Paper/10.1117/12.2251029?origin_id=x4318
<https://www.spiedigitallibrary.org/conference-proceedings-of-spie/10045/1/Wide-field-OCT-angiography-by-using-swept-source-OCT-in/10.1117/12.2251029.short?SSO=1>
46. Novais EA, Baumal C. **The Clinical Utility of OCT Angiography.** *Review of Ophthalmology website.* January 10, 2017
<https://www.reviewofophthalmology.com/article/the-clinical-utility-of-OCT-angiography>
47. Coffey VC. **Advanced OCT: Making Waves in the Market.** *Opt Photonics News.* 2016;27(9):26-33
<https://www.osapublishing.org/opn/abstract.cfm?uri=opn-27-9-26>
48. Lavinsky F, Lavinsky D. **Novel Perspectives on Swept-Source Optical Coherence Tomography.** *Int J Retina Vitreous.* 2016 Nov 1;2(1):25 <https://www.ncbi.nlm.nih.gov/pubmed/27847643>
https://www.ncbi.nlm.nih.gov/pmc/articles/PMC5088466/pdf/40942_2016_Article_50.pdf
49. Shahidzadeh A, Kim AY, Aziz HA, Durbin MK, Puliafito C, Kashani AH. **Widefield Swept-Source Optical Coherence Tomography Angiography.** *Invest Ophthalmol Vis Sci.* 2016 Sep;57(12):445
<https://iovs.arvojournals.org/article.aspx?articleid=2558091&resultClick=1>
50. Kubach S, Luu JY, Lee S, Jung JJ, Rosenfeld PJ, Gregori G. **Importance of Sampling Density in the Analysis of Optical Coherence Tomography Angiography.** *Invest Ophthalmol Vis Sci.* 2016 Sep;57(12):4613
<https://iovs.arvojournals.org/article.aspx?articleid=2557949&resultClick=1>
51. Gregori G, Rosenfeld PJ, Roisman L, Schaal KB. **Automated Retinal Segmentation for Widefield OCT, with Applications to OCT Angiography.** *Invest Ophthalmol Vis Sci.* 2016 Sep;57(12):446
<https://iovs.arvojournals.org/article.aspx?articleid=2559294&resultClick=1>
52. Wang RK, Zhang A, Choi WJ, Zhang Q, Chen CL, Miller A, Gregori G, Rosenfeld PJ. **Wide-Field Optical Coherence Tomography Angiography Enabled by Two Repeated Measurements of B-Scans.** *Opt Lett.* 2016 May15;41(10):2330-3 <https://www.ncbi.nlm.nih.gov/pubmed/27176995>
53. Huang Y, Zhang Q, Thorell MR, An L, Durbin MK, Laron M, Sharma U, Gregori G, Rosenfeld PJ, Wang RK. **Swept-Source OCT Angiography of the Retinal Vasculature Using Intensity Differentiation-Based Optical Microangiography Algorithms.** *Ophthalmic Surg Lasers Imaging Retina.* 2014 Sep-OCT;45(5):382-89
<https://www.ncbi.nlm.nih.gov/pmc/articles/PMC4286454/>
<https://www.ncbi.nlm.nih.gov/pmc/articles/PMC4286454/pdf/nihms648133.pdf>

Tumors

1. Russell JF, Shi Y, Gregori G, Rosenfeld PJ. **Longitudinal Swept Source OCT Angiography of Juxtapapillary Retinal Capillary Hemangioblastoma.** *Ophthalmol Retina.* 2020 Sep;4(9):956-958. <https://pubmed.ncbi.nlm.nih.gov/32438081/>
2. Reich M, Glatz A, Boehringer D, Evers C, Daniel N, Bucher M, Ludwig F, Nuessle S, Lagrèze WA, Maloca PM, Lange C, Reinhard T, Agostini H, Lang SJ. **Comparison of Current Optical Coherence Tomography Angiography Methods in Imaging Retinal Hemangioblastomas.** *Transl Vis Sci Technol.* 2020 Jul 8;9(8):12. <https://tvst.arvojournals.org/article.aspx?articleid=2770266&resultClick=1>
<https://pubmed.ncbi.nlm.nih.gov/32855859>
3. Breazzano MP, Bacci T, Wang Sr. H, Francis JH, Yannuzzi LA. **Bacillary Layer Detachment in Bilateral Diffuse Uveal Melanocytic Proliferation Masquerading as Neovascular AMD.** *Ophthalmic Surg Lasers Imaging Retina.* 2020 Jul 1;51(7):413-417. <https://pubmed.ncbi.nlm.nih.gov/32706900/>
4. Pellegrini M, Corvi F, Invernizzi A, Ravera V, Cereda MG, Staurenghi G. **Swept-Source Optical Coherence Tomography Angiography In Choroidal Melanoma: An Analysis of 22 Consecutive Cases.** *Retina.* 2019 Aug;39(8):1510-1519. <https://pubmed.ncbi.nlm.nih.gov/29863536>
5. Arrigo A, Pierro L, Sacconi R, Querques G, Bandello F. **Bilateral Choroidal Osteoma Complicated by Bilateral Choroidal Neovascularization.** *Ophthalmic Surg Lasers Imaging Retina.* 2019 Jun 1;50(6):398-400. <https://pubmed.ncbi.nlm.nih.gov/31233159>
6. Ito Y, Ohji M. **Long-Term Follow-up of Congenital Simple Hamartoma of the Retinal Pigment Epithelium: A Case Report.** *Case Rep Ophthalmol.* 2018;9(1):215 <https://www.ncbi.nlm.nih.gov/pubmed/29681839>
7. Pellegrini M, Corvi F, Ravera V, Staurenghi G. **Swept-Source Optical Coherence Tomography Angiography in Choroidal Melanoma.** *Invest Ophthalmol Vis Sci.* 2017 Jun;58(8):1694 <https://iovs.arvojournals.org/article.aspx?articleid=2637815&resultClick=1>
8. Pellegrini M, Staurenghi G. **Swept-Source Optical Coherence Tomography Angiography Imaging in a Case of Uveal Melanoma.** *Ophthalmology.* 2017 May;124(5):729 <https://www.ncbi.nlm.nih.gov/pubmed/28433129>

Vascular Occlusions

1. Costanzo E, Parravano M, Gilardi M, Cavalleri M, Sacconi R, Aragona E, Varano M, Bandello F, Querques G. **Microvascular Retinal and Choroidal Changes in Retinal Vein Occlusion Analyzed by Two Different Optical Coherence Tomography Angiography Devices.** *Ophthalmologica.* 2019;1
<https://www.ncbi.nlm.nih.gov/pubmed/30721901>
2. Tsai G, Banaee T, Conti FF, Singh RP. **Optical Coherence Tomography Angiography in Eyes with Retinal Vein Occlusion.** *J Ophthalmic Vis Res.* 2018;13(3):315 <https://www.ncbi.nlm.nih.gov/pubmed/30090189>
3. Motulsky E, Zheng F, Liu G, Gregori G, Rosenfeld PJ. **Swept-Source OCT Angiographic Imaging of a Central Retinal Vein Occlusion During Pregnancy.** *Ophthalmic Surg Lasers Imaging Retina.* 2018;49(3):206
<https://www.ncbi.nlm.nih.gov/pubmed/29554389>
4. Freund KB, Sarraf D, Leong BCS, Garrity ST, Vupparaboina KK, Dansingani KK. **Association of Optical Coherence Tomography Angiography of Collaterals in Retinal Vein Occlusion with Major Venous Outflow through the Deep Vascular Complex.** *JAMA Ophthalmol.* 2018;136(11):1262 <https://www.ncbi.nlm.nih.gov/pubmed/30352115>
5. Arrigo A, Carnevali A, Sacconi R, Querques L, Querques G, Bandello F. **Spontaneous Retinal-Choroidal Anastomosis in a Case of Branch Retinal Vein Occlusion.** *Am J Ophthalmol Case Rep.* 2018;11:92
<https://www.ncbi.nlm.nih.gov/pubmed/30003175>
6. Zhang Q, Chen C-L, Chu Z, Wang RK. **Wide Field OCT Angiography by Using Swept-Source OCT in Living Human Eye.** *Ophthalmic Technologies XXVII.* 2017;10045:100450V
https://spie.org/Publications/Proceedings/Paper/10.1117/12.2251029?origin_id=x4318
<https://www.spiedigitallibrary.org/conference-proceedings-of-spie/10045/1/Wide-field-OCT-angiography-by-using-swept-source-OCT-in/10.1117/12.2251029.short?SSO=1>
7. Jones BP, Chen MH, Jung JJ, Hoang QV, Inoue M, Bala C, Freud KB, Yannuzzi LA, Rofagha S, Lee A. **Comparison of OCT Angiography and Conventional Fluorescein Angiography in the Evaluation of Collateralization in Acute Versus Chronic Branch or Hemi Retinal Vein Occlusion.** *Invest Ophthalmol Vis Sci.* 2016 Sep;57(12):5473
<https://iovs.arvojournals.org/article.aspx?articleid=2563567&resultClick=1>
8. Kuehlewein L, An L, Durbin MK, Sadda SR. **Imaging Areas of Retinal Nonperfusion in Ischemic Branch Retinal Vein Occlusion with Swept-Source OCT Microangiography.** *Ophthalmic Surg Lasers Imaging Retina.* 2015;46(2):249
<https://www.ncbi.nlm.nih.gov/pubmed/25707052>
<https://www.healio.com/ophthalmology/journals/osli/2015-2-46-2/{d4c82e7e-1918-45bc-8c9c-6478166f3393}/imaging-areas-of-retinal-nonperfusion-in-ischemic-branch-retinal-vein-occlusion-with-swept-source-OCT-microangiography>
9. Kashani AH, Lee SY, Moshfeghi A, Durbin MK, Puliafito CA. **Optical Coherence Tomography Angiography of Retinal Venous Occlusion.** *Retina.* 2015;35(11):2323
<https://www.ncbi.nlm.nih.gov/pubmed/26457395>
<https://insights.ovid.com/pubmed?pmid=26457395>
10. Lee SY, Matsunaga D, Yi J, Durbin MK, Puliafito C, Kashani AH. **Swept-Source OCT Angiography (OCTA) of Subjects with Retinal Vein Occlusions.** *Invest Ophthalmol Vis Sci.* 2015 Jun;56(7):3345
<https://iovs.arvojournals.org/article.aspx?articleid=2333203&resultClick=1>

CE 0297



Carl Zeiss Meditec, Inc.
5160 Hacienda Drive
Dublin, CA 94568
USA
www.zeiss.com/swept-source
www.zeiss.com/med/contacts



Carl Zeiss Meditec AG
Goeschwitzer Str. 51-52
07745 Jena
Germany
www.zeiss.com/swept-source
www.zeiss.com/med/contacts

EN_31_200_1058II Printed in the United States. CZ-X/2020 International edition: Only for sale in selected countries. The contents of the compendium may differ from the current status of approval of the product or service offering in your country. Please contact our regional representatives for more information. Subject to changes in design and scope of delivery and as a result of ongoing technical development. PLEX Elite is either a trademark or registered trademark of Carl Zeiss Meditec AG or other companies of the ZEISS Group in Germany and/or other countries.
© Carl Zeiss Meditec, Inc. 2020. All rights reserved.